



The ROYAL COLLEGE of
OPHTHALMOLOGISTS

Clinical Guideline

Idiopathic Full Thickness Macular Holes

September 2024



[The Royal College of Ophthalmologists](#) (RCOphth) is the professional body for eye doctors, who are medically qualified and have undergone or are undergoing specialist training in the treatment and management of eye disease, including surgery. As an independent charity, we pride ourselves on providing impartial and clinically based evidence, putting patient care and safety at the heart of everything we do. Ophthalmologists are at the forefront of eye health services because of their extensive training and experience. The Royal College of Ophthalmologists received its Royal Charter in 1988 and has a membership of over 4,000 surgeons of all grades. We are not a regulatory body, but we work collaboratively with government, health and charity organisations to recommend and support improvements in the coordination and management of eye care both nationally and regionally.



**The ROYAL COLLEGE of
OPHTHALMOLOGISTS**

© The Royal College of Ophthalmologists 2024. All rights reserved.

For permission to reproduce any of the content contained herein please contact contact@rcophth.ac.uk

Contents

Introduction	4
Guideline Objectives	5
Macular Hole Guidelines Group	5
Objectives	6
Guideline Methodology	7
GRADE Levels of Evidence	7
Sign 50 Grades of Recommendation	8
Scottish Intercollegiate Guidelines Network (SIGN) Grades for Evidence	8
Abbreviations	9
Acknowledgements	10
Sections:	
1. Epidemiology	11
2. Aetiology	13
3. Training and Facilities	17
4. Investigation and Referral	18
5. Classification	23
6. Different Management Options	27
7. Vitrectomy Considerations	36
8. Outcomes	54
9. Follow-up and Further Management	58
10. Complications	61
11a. Revision Surgery for Persistent iFTMH After Unsuccessful Surgery	63
11b. Reopened iFTMH After Initially Successful Primary Surgery	65
12. Topical Treatments for Primary iFTMH, Persistent and Re-opened Holes	67
Appendix 1	68
Appendix 2	77
References	106

Introduction

Background and importance of condition

Full thickness macular holes (FTMH) are a relatively common and visually disabling condition. They can occur as primary or idiopathic FTMH (iFTMH), and less commonly secondary, associated with a range of other ocular conditions including trauma, retinal detachment, and myopia. iFTMH occur because of age-related vitreous changes, that result in vitreous traction on the central fovea ('vitreomacular traction' (VMT)) and full thickness hole formation in some people. iFTMH are bilateral in approximately 10% of affected individuals, with a peak age of onset of 70 years and being approximately twice as common in women as men. If left untreated the hole typically enlarges and results in a reduction in visual acuity (VA) below the definition of blindness in the eye affected and typically less than 1.0 logMAR (20/200). IFTMH are a type of vitreo-retinal interface abnormality (VRIA). A study using data from the UK Biobank found that VRIA were one of the four most prevalent causes of identifiable visual impairment in the UK.

The management of people presenting with iFTMH should aim to accurately identify those who might benefit from treatment and then offer treatment in a timely way which optimises outcomes.

All treatments are aimed at closing the hole to restore vision. The surgical procedure vitrectomy with endotamponade, has been the mainstay of treatment since its introduction in 1991 by Kelly and Wendel, and can close the hole in most cases. Typically, if the hole is closed, vision improves by a mean of 0.3 logMAR, although the level of vision after surgery is very variable depending on the baseline level, with only 35% achieving a driving vision level of VA (0.3 logMAR (6/12)) dependant in turn on case mix. A large UK retrospective electronic records study in 2013 showed it was the second most common indication for retinal surgery, with approximately 3500 surgeries carried out in the UK per annum, rising with the ageing population.

Clinical need for a guideline

A range of additional surgical choices have been proposed to improve the success of vitrectomy for iFTMH including tamponade selection, internal limiting membrane (ILM) peeling and other adjuvants. Narrow gauge surgery and combined phacovitrectomy have been suggested to speed postoperative recovery and have been widely adopted. The utility of postoperative face down positioning once considered a vital part of the treatment has been questioned, and the time course of visual recovery, important for planning a return to normal activities following treatment studied. Additionally, alternative treatments including expansile gas injections without vitrectomy, and enzymatic vitreolysis have been proposed as alternatives. The patient pathway from initial presentation to undergoing treatment has changed with the widespread availability of optical coherence tomography (OCT). OCT is a quick, painless, non-invasive imaging system which captures a cross-sectional image of the central retina. OCTs are becoming more common in community care, with the large optometry chains investing in the technology. They offer the ability to diagnose and classify holes accurately without the need for experienced funduscopy, permitting appropriate and more timely referral pathways. These choices are important for all, from the people effected, to the surgeons, nurses, optometrists, and other allied healthcare professional involved in the management of people with iFTMH.

The evidence-base to guide decision making in macular hole management is one of the more advanced domains in vitreoretinal surgery with a large range and number of RCTs and systematic reviews. iFTMH affect all ethnicities and are an internationally important cause of visual morbidity.

Guideline objectives

The aims of the guideline are to evaluate and summarise the clinical evidence relating to the management and treatment of people with iFTMH, that can be used nationally and internationally to benefit patients with this condition.

Target Audience: Ophthalmologists, vitreo-retinal surgeons, ophthalmic nurses, optometrists, and other ophthalmic healthcare practitioners in any setting where people with iFTMH are referred, evaluated and/or treated, as well as the patients themselves and their carers.

Scope: Initial presentation through to discharge, including guidance on referral.

Population studied: People with primary 'idiopathic' full thickness macular holes (iFTMH). iFTMH that don't close after surgery ('Persistent' holes) and holes that initially close and then reopen ('Re-opened' holes) are also considered. Partial thickness macular holes and secondary full macular thickness holes are not included but will each be covered in future RCOphth concise practice point publications.

Macular Hole Guidelines Group

Chair

David Steel

Sunderland and Newcastle, England

Medical Retina representative

Sobha Sivaprasad

London, England

UK Vitreoretinal Surgeon representatives

Noemi Lois

Belfast, Northern Ireland

Tim Jackson

London, England

Assad Jalil

Manchester, England

David Yorston

Glasgow, Scotland

Graham Duguid

London, England

Trainee Ophthalmologist representative

Boon Teh

Sunderland, England

Vitreoretinal Nurse Specialist representative

Yvonne Kana

London, England

Optometry representatives

John Lawrenson

London, England

Simon Berry

Durham, England

International Vitreoretinal Surgeon representatives

Varun Chaudhary

Canada (CRS)

Marta Figueroa

Spain (Euretina representative)

Kevin Blinder

USA (ASRS)

Patient and Public involvement

Geraldine Hoad

England – Macular Society representative

Note on minimal important differences in macular hole closure rates and postoperative visual acuity with treatment trials.

Macular hole closure rates are typically high, around 80-90% following vitrectomy surgery dependant on a range of factors discussed further throughout this guideline. There is no agreed minimal important difference (i.e., an amount that surgeons and patients agree is clinically relevant and would change decision making) in closure rate. This would depend on the estimated closure rates of the precise features of the iFTMH being treated and the risks/advantages of the new treatment being evaluated. 10% has been used as¹² a non-inferiority margin in trials of macular holes with interventions such as different gases, and face down positioning.

Similarly, there is no agreed clinically relevant difference in visual acuity, although it usually taken as being 0.12 logMAR or over (6 or more ETDRS letters) at 6 months postoperatively. This time point is chosen as it is known that vision improves with time following surgery, but VA stabilises in most cases at six months or more postoperatively. It is also known however, that sometimes especially in larger holes and those treated with adjuvant procedures vision can continue to improve for a year or more. As with closure the clinically relevant difference will vary to some extent by the baseline visual acuity, with a smaller improvement being more relevant as visual acuity improves. It is also known that patient satisfaction after surgery can be more related to improvements in metamorphopsia than visual acuity³⁴. Further research to clarify meaningful differences to guide trials is needed.

Visual acuity can be measured and recorded in several ways. We have presented visual acuities as logMAR with a Snellen equivalent in metres (e.g., 6/12, equivalent to 20/40 or 0.3 logMAR) in buckets for clarity. For visual acuity improvement we have used logMAR only. It should be noted 0.1 logMAR is equal to 5 ETDRS letters.

Objectives

The guideline group decided on the following key sections:

1. Epidemiology
2. Aetiology
3. Training and facilities
4. Investigation and referral
5. Classification
6. Management options
7. Considerations specific to vitrectomy
8. Outcomes
9. Follow-up and further management
10. Complications
11. Management of persistent and reopened iFTMH following initial surgery
12. Topical treatments for IFTMH

Guideline Methodology

Key questions for the guideline were developed using the PICO framework to provide a structured basis for identifying the evidence. A systematic review of the literature was undertaken using the explicit search strategies devised in collaboration with an information specialist from the London School of Hygiene and Tropical Medicine. (See appendix) Databases searched include Medline, Embase, and the Cochrane Library for literature published between 1991 & 2022. The literature search focused on the best available evidence to address the key review questions by including the following types of evidence; Published guidelines, systematic reviews, randomised controlled trials, prospective and retrospective cohort and case control studies and case series. Reference lists of publications were searched for additional evidence sources. Papers not published in the English language and conference abstracts were excluded.

The evidence base for this guideline was identified and synthesized in accordance with previously accepted Royal College of Ophthalmologists (RCOphth) guideline methodology. Each of the selected papers was evaluated by the guideline development group using standard checklists before conclusions were considered as acceptable evidence.

For key treatment decisions and choices, several summary evidence statements were composed. The evidence sources that underpin these statements were graded using the Scottish Intercollegiate Guidelines Network (SIGN) 50 grades of evidence (1++ to 4). The overall level of evidence that these statements were based upon were graded using the SIGN 50 grading hierarchy (A to D), and with the Grading of Recommendations, Assessment, Development, and Evaluations (GRADE) working group (High to very low) according to the strength of the evidence underpinning them.

GRADE Levels of Evidence

High = Further research is very unlikely to change our confidence in the estimate of effect (e.g., large, well conducted, definite RCTs).

Moderate = Further research is likely to have an important impact on our confidence in the estimate of effect and may change the estimate (e.g., small or potentially biased RCTs, non-randomised comparative studies).

Low = Further research is very likely to have an important impact on our confidence in the estimate of effect and is likely to change the estimate (e.g., observational studies).

Very low = Any estimate of effect is very uncertain.

Sign 50 Grades of Recommendation

The grade of recommendation relates to the strength of the evidence on which the recommendation is based. It does not reflect the clinical importance of the recommendation.

- A:** At least one meta-analysis, systematic review, or RCT rated as 1++, and directly applicable to the target population; or A body of evidence consisting principally of studies rated as 1+, directly applicable to the target population and demonstrating overall consistency of results.
- B:** A body of evidence including studies rated as 2++, directly applicable to the target population, and demonstrating overall consistency of results; or Extrapolated evidence from studies rated as 1++ or 1+
- C:** A body of evidence including studies rated as 2+, directly applicable to the target population and demonstrating overall consistency of results; or Extrapolated evidence from studies rated as 2++
- D:** Evidence level 3 or 4; or Extrapolated evidence from studies rated as 2+

Scottish Intercollegiate Guidelines Network (SIGN) Grades for Evidence

- 1++** High quality metaanalyses, systematic reviews or RCTs with a very low risk of bias
- 1+** Well conducted metaanalyses, systematic reviews or RCTs with a low risk of bias
- 1-** Metaanalyses, systematic reviews or RCTs with a high risk of bias
- 2++** High quality systematic reviews of case control or cohort studies. Case control or cohort studies with a very low risk of confounding or bias and a high probability that the relationship is causal.
- 2+** Case control or cohort studies with a low risk of confounding or bias and a moderate probability that the relationship is causal.
- 2-** Case control or cohort studies with a high risk of confounding or bias and a significant risk that the relationship is not causal
- 3** Case reports, case series
- 4** Expert opinion

Abbreviations

Abbreviation	Description	Abbreviation	Description
BBG	Brilliant Blue G dye	MLD	Minimum linear diameter
DD	Disc diameter	OCT	Optical coherence tomography
DONFL	Dissociated optic nerve fibre layer	PPV	Pars plana vitrectomy
ELM	External limiting membrane	PTMH	Partial thickness macular hole
ERM	Epiretinal membrane	PVD	Posterior vitreous detachment
ERP	Epiretinal proliferation	RCOphth	Royal College of Ophthalmologists, UK
ETDRS	Early treatment diabetic retinopathy study chart	RCT	Randomised controlled study
FTMH	Full thickness macular hole	SANFL	Subacute nerve fibre layer swelling
ICG	Indocyanine green Dye	SDOCT	Spectral domain OCT
iFTMH	idiopathic full thickness macular hole	SR	Systematic review
ILM	Internal limiting membrane of retina	VA	Visual acuity
IVTS	International vitreomacular traction study group	VMA	Vitreomacular attachment
LMH	Lamellar macular hole	VMT	Vitreomacular traction
logMAR	Logarithm of the minimum angle of resolution	VRIA	Vitreoretinal interface abnormality
mfERG	multifocal electroretinogram		

Acknowledgements

The Royal College of Ophthalmologists would like to thank **Iris Gordon, Information Specialist, London School of Hygiene and Tropical Medicine** for her assistance in searching the evidence base.

Funding

Royal College of Ophthalmologists, UK

TBC

1. Epidemiology

1a. What is the incidence and prevalence of iFTMH

The incidence of iFTMH has been reported to range between 3.14 to 7.8 per 100,000 of the general population per year.^{5,6,7,8} Participants in these studies were majority white populations apart from one Korean study. Another US study on health insurance beneficiaries aged 40 years or more estimated the cumulative incidence to be around 41.1 per 100 000 person-years.⁹

1b. What are the demographic features of patients with iFTMH?

Age

Numerous published studies have reported that the incidence of iFTMH peaks between age 60 to 70 on average.^{5, 6, 8, 9, 11}

Although the likelihood of developing FTMH was found to be higher with an increase in age, the change appeared to be non-linear. Studies have demonstrated reducing incidence of FTMH after age of 70,⁸ 75,⁸ and 80.^{5,6,17}

Sex

iFTMH is a condition with a female preponderance. Overall, it was estimated that females are between 2 to 3.3 times more likely to be affected than males.^{5, 6, 8, 9, 17, 18, 19, 22}

There are however certain age groups whereby males were affected more. Cho et al.⁸ showed higher male to female ratio for age group under 30 and above 75 years old. Similarly, Ali et al.⁹ reported higher male incidence for age <36 and >76 year. Two other studies concurred with the findings and demonstrated more males aged 80 and over had iFTMH.^{5, 6}

One possible explanation of higher male incidence in the older age group is due to difference in posterior vitreous detachment (PVD) between male and female.⁶ Studies have reported an earlier onset of PVD and a generally higher proportion of PVD in females compared with males.^{24,25,26}

On the other hand, male prevalence in younger age groups is likely due to secondary FTMH from other causes such as trauma instead of iFTMH.⁵ It was noted that patients with traumatic FTMH tend to be male and younger.^{27,28} A Tasmanian study also confirmed higher male incidence in younger age groups when analysis was done including both primary and secondary FTMH.⁵

Ethnicity

Several studies have illustrated the variations in iFTMH characteristics in different ethnic groups.

One US study found Asian Americans to have 177% increased risks of developing iFTMH compared to White individuals.⁹ Asians have also been found to present with larger iFTMH compared to white patients.^{18,29,30}

Another UK study found iFTMH to be more common in Afro-Caribbean patients. They also present younger compared to White and Asian patients.^{19, 31} Similarly, it was noted Afro-Caribbean patients present with larger iFTMH compared to White patients.^{18, 19, 29, 30}

One potential reason for this difference could be due to baseline foveal anatomic variations between the ethnic groups. Few studies have reported a wider foveal floor amongst Afro-Caribbean and Asian population comparing to White.^{22,32,33} A study demonstrated a significant association between foveal floor width and size of iFTMH, with eyes of larger iFTMH having broader foveal floor sizes in the fellow eyes,²² possibly explaining the variability of iFTMH size between different ethnic groups.

1c. What is the incidence in the fellow eye?

The incidence of fellow eye involvement varies widely with different publications.

It has been estimated that around 2% – 7% have bilateral iFTMH at presentation.^{34,35,36,37,38,39,40}

The overall incidence of developing iFTMH in the fellow eye ranges from 5.3% to 22%.^{5,6,12,18,19,21,37,39,40}

A few studies have also carried out subgroup analyses and found higher incidences of fellow eye involvement of between 11.9% and 28.6% in those without PVD.^{20,36,37,44} One study showed none of the fellow eyes with PVD at presentation developed iFTMH over an average of 47 months follow-up, although rare cases have been reported.³⁷

Other characteristics found to increase the risks of development of iFTMH in fellow eye are described in Section 2.

Summary

iFTMH more commonly affect females in the age group of 60-70 years old. The majority of iFTMHs are unilateral, but there is up to a 29% risk of fellow eye involvement depending on vitreous status.

2. Aetiology

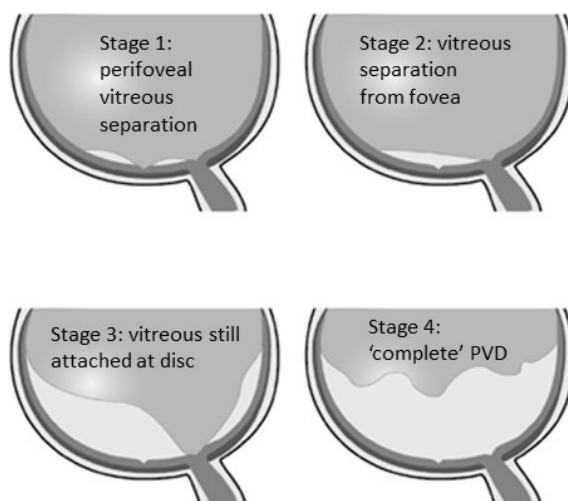
- a. What are the aetiological factors for full thickness macular holes?
- b. What are the risk factors for full thickness macular holes?
- c. What are the associated symptoms of full thickness macular holes?
- d. What are the risk factors for occurrence in the fellow eye?

2a. What are the aetiological factors for full thickness macular holes?

Full-thickness macular holes (FTMH) can occur as an idiopathic primary event (iFTMH, the subject of these guidelines) or secondary to other abnormalities such as high myopia, trauma, chronic macular oedema, intraocular inflammation, retinal detachment, or retinal dystrophies.

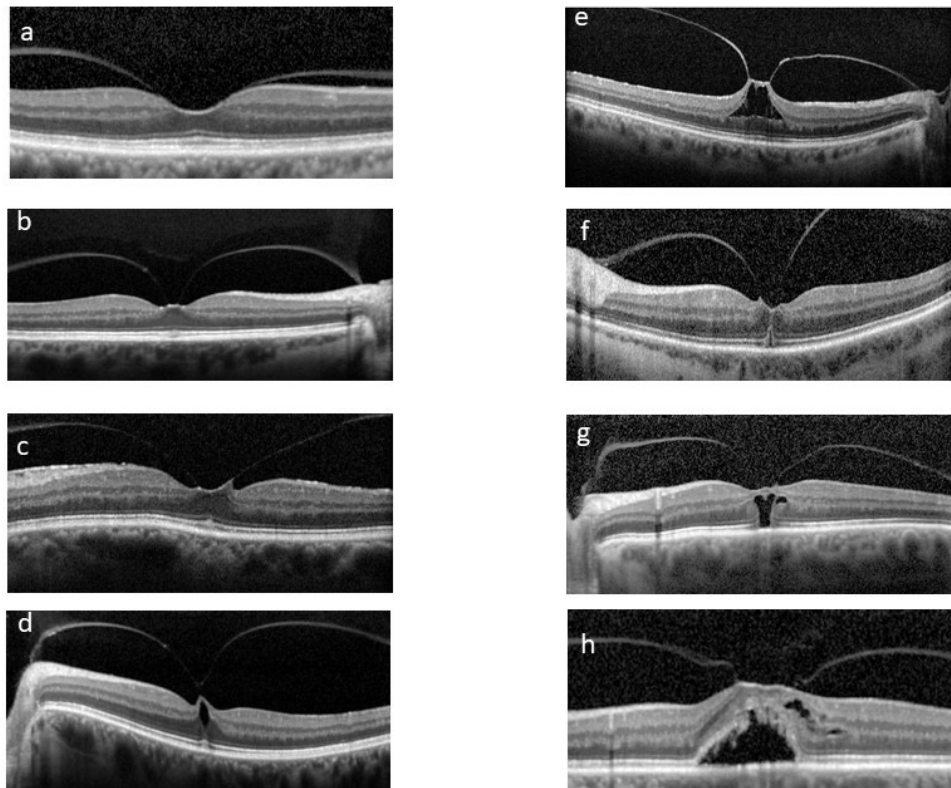
Formation of iFTMHs can be thought of as a sequence of complex mechanical events involving vitreous traction on the foveal centre as the initiating event.^{47,48,49} Age-related posterior vitreous detachment (PVD), defined as separation between the posterior vitreous cortex and the ILM of the retina, often underlies the generation of this vitreous traction. The understanding of PVD is evolving over time, and currently the most accepted view is that PVD begins in the perifoveal macula.^{50,51,52} (Figure 1).

Figure 1: Normal age-related vitreous separation from the retina occurs progressively with 4 stages recognised. Initially separation occurs peri-foveally with vitreomacular attachment (stage 1), followed by foveal separation (stage 2), then more widespread separation except at the optic disc head (stage 3) before finally separating at the disc (stage 4) when some patients present with floaters, retinal photopsia and retinal tears. Idiopathic full thickness macular holes are thought to occur largely as a result of vitreomacular traction because of pathological stage 1 vitreous separation.



The progression of perifoveal PVD, in combination with abnormal focal attachment of vitreous to the fovea, can cause cleavage between the Müller cell cone and photoreceptors, giving rise to intraretinal cystic lesions seen on OCT.^{52,53,54,55} As this anteroposterior traction continues, the force causes breaks in both ILM and external limiting membrane (ELM), leading to retinal dehiscence and iFTMH (Figure 2). There have also been suggestions that the dynamic tractional forces generated by posterior cortical vitreous movement during eye rotation may play a contributing role.^{50,56}

Figure 2: a (vitreomacular attachment, VMA), b-c (mild vitreomacular traction, VMT), d (VMT with inner retinal cysts and signs of early outer retinal traction with cotton ball sign), e (VMT with inner retinal cleavage), f (VMT with outer retinal traction and early dehiscence), g (VMT and outer retinal dehiscence), h (VMT with subretinal fluid and outer retinal dehiscence).



The degree of outer retinal layer loss appears to correlate with the extent and intensity of vitreomacular traction (VMT), with wider attachment causing more extensive loss of photoreceptors.⁵⁷ Retinal glial proliferation can take place in an attempt to self-repair, with variable success.^{58,59} Paradoxically, when self-repair fails, glial cell migration around the hole edges can occur onto the perifoveal ILM. These can then exert tangential traction with progressive contraction, leading to enlargement of the iFTMH.⁵⁸ Subsequently, the direct communication of vitreous fluid and outer retina causes hydration, leading to the hole edges to thicken and evert.^{60,61,62} This further aggravates the impedance of glial migration that might otherwise help close the iFTMH.⁵⁹

Summary

iFTMH most commonly occurs secondary to age related posterior vitreous separation. Abnormal focal foveal attachment during this process can exert anteroposterior traction on the central fovea and initiate a sequence of events leading to development and enlargement of iFTMH.

2b. What are the risk factors for iFTMH?

Age

- Increasing age is associated with increased risks of iFTMH, however the change appears to be non-linear. (A) ⁹ (see *Epidemiology section*).
- The effect of age corresponds with PVD, the initiating event for iFTMH. (B) ⁸

Sex

- Females have a higher risk than males. (A-D) ^{8,9} (see *Epidemiology section*).

Ethnicity

- One US study found Asian Americans had an increased risk of iFTMH compared to white individuals. (A) ⁹
- Two UK based studies reported that Asian and Afro-Caribbean patients presented with larger iFTMHs compared to white patients. (E, F) ^{29,30}

Axial length

- Increased axial length is thought to be a risk factor for macular hole formation. (G) ⁶⁵ It has been proposed that the dynamic forces acting about the axis of ocular rotation are higher in longer eyes, resulting in a greater propensity for iFTMH formation.⁶⁵
- It was also noted that age at the onset of iFTMHs significantly decreased as the magnitude of myopia increased. (H) ⁶⁶

2c. What are the associated symptoms of full thickness macular holes?

The most common symptom of macular hole is reduced and blurred vision, which tends to worsen with increasing hole size.⁴³ Other symptoms include central scotoma often associated with metamorphopsia and/or micropsia and rarely photopsia.^{51,67} Symptoms may depend on ocular dominance (i.e., may not be so noticeable to patients if the eye effected is the non-dominant eye).

2d. What are the fellow eye risk factors for occurrence of macular hole in the fellow eye?

The following four factors have moderate to high certainty evidence:

- Presence of vitreomacular traction: 20% - 35.5%.⁴⁰
- Absence of PVD or presence of vitreomacular adhesion: 8.7% - 18.5%. ^{20,40,41,44,68}
- Presence of outer foveal defect: 27.8% - 100%. ^{35,40,68}
- Presence of inner foveal cyst: 16.7% - 57%. ^{40,41,53,69}

Two other factors have been suggested with very low certainty evidence:

- Possibly the presence of foveal hyper-reflective stress-line or foveal crack sign: 50% - 52.6%.^{42,47}
- Possibly multifocal electroretinography (mfERG) showing lower amplitude and higher implicit time: 7.4% - 23.9%.^{73,74}

Practice point

Counsel patients regarding the risks of subsequent fellow eye involvement and to self-monitor for macular hole symptoms, particularly in patients with fellow eyes with vitreomacular traction/adhesion, outer foveal defect or inner foveal cysts.

3. Training and Facilities

3a. Training

Macular hole surgery should be undertaken under the supervision of a fully trained vitreo-retinal specialist. Typically, this means specialist vitreo-retinal fellowship training of 1 to 2 years before appointment to the consultant (independent specialist) grade. During this fellowship training, increased hands-on experience in macular hole surgery is obtained in addition to other vitreo-retinal procedures. Studies show that equally good results in terms of hole closure and visual acuity can be achieved by trainees operating under consultant supervision as by the specialists themselves.^{75,76}

3b. Facilities

Surgery for macular holes should take place in an operating theatre fully equipped for vitreo-retinal surgery. Surgery can be undertaken under general or local anaesthesia as a day-case procedure. A posterior segment vitrectomy machine is required, along with the range of other vitreoretinal equipment and tamponade agents. Vitrectomy forceps, other devices to aid ILM peel initiation (e.g., scrapers and loops), and adjuvant dyes to stain the ILM (brilliant blue G, indocyanine green and trypan blue) are required as per the choice of the individual surgeon cryotherapy and laser (endolaser and indirect laser) should also be available as required to treat retinal breaks. The nursing and support staff in the facility should be adequately trained and experienced in assisting vitreoretinal procedures.

Suitable operating microscopes are currently of two kinds. The commonly used conventional microscope allows for direct binocular visualisation, preferably with an external monitor and assistant piece. Widefield viewing systems such as the Resight (Zeiss), BIOM (Oculus Inc.) or EIBOS (Haag-Streit) are desirable and ideally integrated with a footswitch-activated or automatic image inverter system. More recently, head-up 3D display systems have become popular, e.g., Ngenuity (Alcon), and have the advantage of allowing a more detailed view for more of the staff present in the operating theatre. Studies have shown that macular hole surgery can be carried out equally effectively using both systems, with a systematic review suggesting reduced retinal light exposure and greater surgeon comfort for the 3D visualisation system over a conventional microscope.^{77,78}

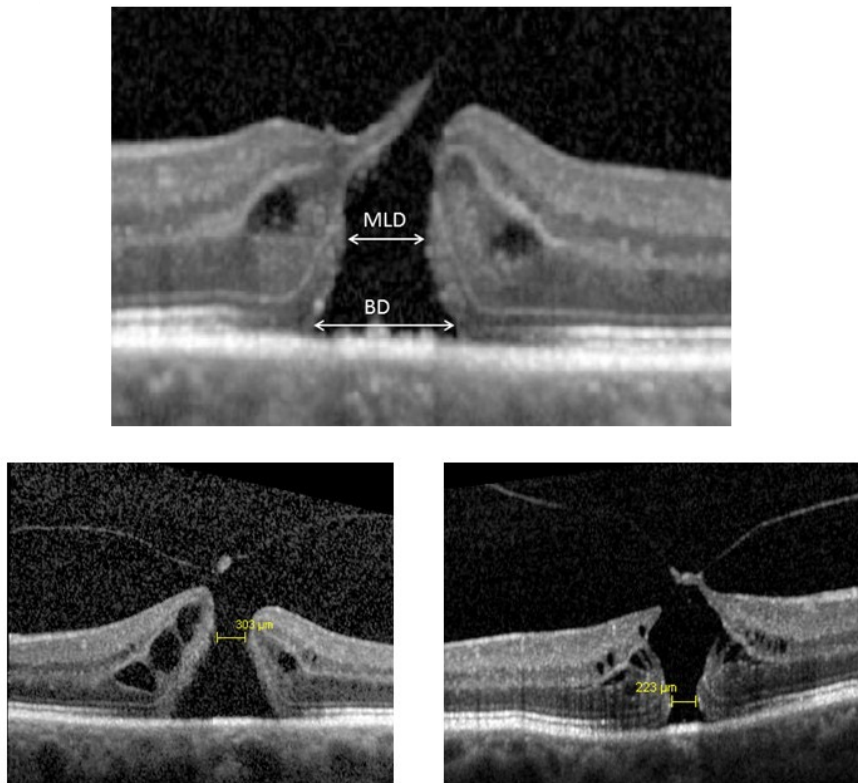
Microscope integrated OCT can provide clinically relevant information to surgeons during surgery but is not considered essential.⁷⁹

4. Investigation and Referral

Background

The shift from slit-lamp biomicroscopic staging of macular holes⁸⁰ to an anatomical classification system using optical coherence tomography (OCT) imaging⁸¹ (see Section 5), has improved the diagnosis, management, follow up and monitoring of iFTMH. OCT allows a detailed evaluation of the vitreoretinal interface and facilitates the differentiation between FTMH and a partial thickness macular hole. The calliper function of the OCT can also be used in routine clinical practice to measure macular hole size with acceptable repeatability^{82,83} an important predictor of postoperative closure and functional recovery following vitreous surgery.^{84,85,86} The minimum linear diameter is the most widely used measure of iFTMH size. (Figure 3)

Figure 3: The minimum linear diameter (MLD) is measured in the OCT slice with the widest hole dimensions; MLD is the minimal width at the approximate mid area of the hole. Two other examples are shown in the lower two pictures. Base diameter is the widest diameter where the hole meets the retinal pigment epithelium.



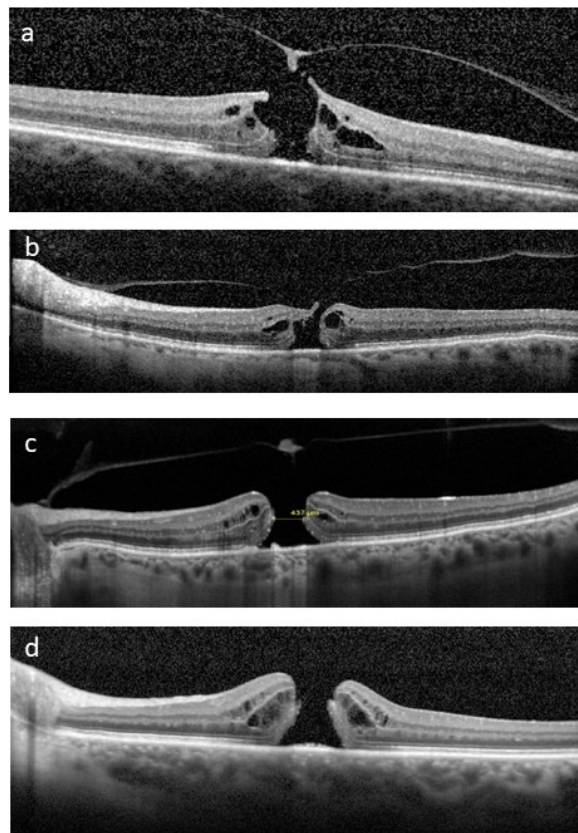
The most widely accepted OCT-based classification system was developed by the International Vitreomacular Traction Study (IVTS) group.⁸¹ The IVTS classification defines an iFTMH as 'a foveal lesion with interruption of all retinal layers from the inner limiting membrane to the retinal pigment epithelium'. FTMH can be further categorised according to the size of the hole and the presence or absence of vitreomacular traction (VMT). iFTMHs can be subdivided into three subgroups based on the minimum linear diameter: small ($\leq 250 \mu\text{m}$), medium ($>250 \mu\text{m}$ to $\leq 400 \mu\text{m}$) and large ($>400 \mu\text{m}$)⁸¹ (See Section 5).

In their role as primary eyecare providers, combined with their increased adoption of advanced imaging technologies,⁸⁷ community optometrists play an important role in triaging referrals of patients presenting with macular holes. Guidance is available from their professional body in the UK on the examination and management of patients presenting with VMT and macular hole.⁸⁸ The clinical guideline recommends OCT imaging for the diagnosis of a macular hole (or referral to a colleague if this is not available) and advocates referral of small, medium and large FTMH's, with OCT monitoring of VMT and impending macular holes depending on symptoms.

a. Spectral domain OCT is the most sensitive and specific way of diagnosing and classifying FTMH (GRADE: MODERATE; SIGN Grade C)

Although a variety of non-invasive retinal imaging modalities have been used to evaluate iFTMH e.g., fundus photography, adaptive optics, fundus autofluorescence, the optimal imaging modality for classification of FTMH is spectral domain OCT. Although a single horizontal line scan through the fovea will usually confirm a FTMH, a series of closely spaced scans may be required to distinguish and measure a small FTMH.⁸¹ The minimum linear diameter, measured horizontally at the narrowest point of the hole on the slice with the widest dimensions should be measured manually using the caliper function of the instrument. (Figure 3) The status of the vitreous in terms of vitreo-macular adhesion should also be documented. (Figure 4).

Figure 4: Four examples of idiopathic full thickness macular holes. A and B (medium sized with VMT), C (large without VMT), D (large without VMT and vitreous separation from disc (stage 4)).



b. Patients with FTMH, regardless of size should be referred for assessment for surgery

(GRADE: MODERATE; SIGN Grade B)

Patients with VMT who have previously had an iFTMH in their fellow eyes (previously called stage 1 macular holes) can usually be safely observed with OCT as 30–50% of these lesions will resolve spontaneously.^{47,90} Referral should be considered depending on symptoms and patients warned to present early if their vision deteriorates. If left untreated iFTMH's are associated with increasing loss of vision (typically less than 6/60). Evidence from randomised controlled clinical trials (RCTs)⁹¹ has shown that macular hole surgery is superior to observation for all iFTMH (See Section 6). Rates of closure of iFTMH following surgery (vitrectomy with a gas or air tamponade) are high, at over 90%,⁸⁶ with low rates of spontaneous closure if untreated.⁹² All patients with small, medium and large iFTMH's should therefore be referred for vitreo-retinal surgery if clinically appropriate and the patient wishes to consider surgery. Hole size and the length of time for which the hole is present before surgery are important predictors of successful hole closure and final functional outcome.^{86,93} (See Section 8).

c. Patients should be referred to consultant-led vitreo-retinal service for further investigation and formulation of a surgical treatment plan. (GRADE: MODERATE, SIGN Grade C)

All patients referred from primary care should have an OCT scan to confirm the diagnosis of iFTMH before referral to a vitreo-retinal service for consideration of a surgical treatment plan. For referrals from sources other than optometrists e.g., general practitioners (GPs), referral should initially be made to a community optometrist with access to OCT imaging for diagnostic confirmation.⁸⁸ Referrals to the Hospital Eye Service for iFTMH should include history and symptoms (including symptom duration), best corrected visual acuity (BCVA), and ideally be accompanied by an OCT scan.

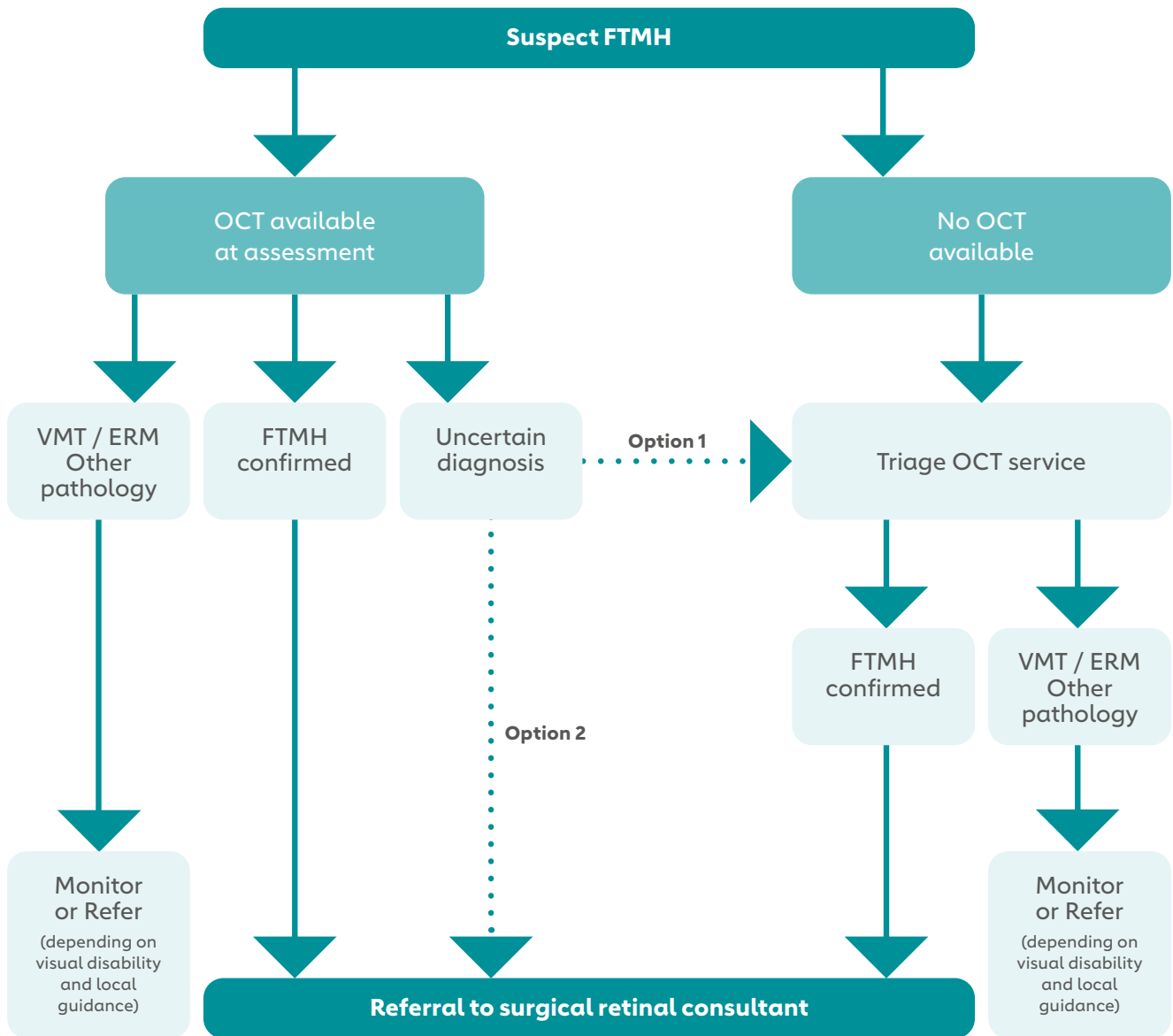
In the absence of an OCT scan that confirms an iFTMH, or where the interpretation of the OCT scan is uncertain; depending on local protocols, patients may be referred through a suitable intermediate OCT triage service for example (Figure 5):

1. Local optometry networks providing a referral refinement service

2. Virtual hospital-based OCT clinics for referral triage. If directly linked to vitreoretinal services these can allow streamlined listing for surgery if appropriate.

To avoid unnecessary time delay, and to streamline the referral pathway, patients should only be referred to medical facilities that can perform vitreo-retinal surgery. This should be a consultant-led vitreoretinal (VR) service that operates to appropriate quality standards.⁹⁵ In the UK vitreoretinal surgeons are expected to have a regular, ideally continuous, audit of their surgical results (including macular hole surgery), which should be presented annually as part of Consultant Appraisal and as part of the periodic revalidation process.⁹⁶ Similar accreditation processes operate in other countries.

Figure 5: Flowchart showing care pathways for patients diagnosed with macular hole and vitreomacular traction starting in community services



d. People with iFTMH should be given the opportunity to discuss their diagnosis, treatment, and likely prognosis, and provided with relevant information in an accessible format.

(SIGN Grade D)

This may include information on the following:

The decision to refer for medical treatment is a shared decision process between the healthcare practitioner and the patient. As such the information given to the patient at the point of referral should reflect that discussion. Relevant information should be provided in an accessible format. Patients should be given information in a timely and appropriate manner. They should be given the opportunity to digest and discuss the information to reach a shared decision.

The format of the information may include verbal discussion, web links or written information. All information should be personalized to the patient's situation and be accessible to the patient in a format they can understand. Written information (on paper or the internet) should be reviewed annually to ensure it is still relevant and accurate. Information may include the diagnosis, the referral process, the prognosis, and potential medical treatment. It is recognised that the referring healthcare practitioner will have less specialist knowledge around macular hole treatment. They should only provide information that is within their professional skill set.

Expected timescales for treatment should also be included in the information given to the patient.

This should reflect the capacity of the local service. Information should include:

- That medical intervention may be possible to improve the vision.
- That a vitreo-retinal surgeon has the necessary skills and knowledge base to discuss treatments.
- That all medical interventions carry a risk and are not guaranteed.
- That peripheral vision is not affected by a macular hole.

Patients should be given appropriate contact details to discuss any new concerns and/or the treatment plan.

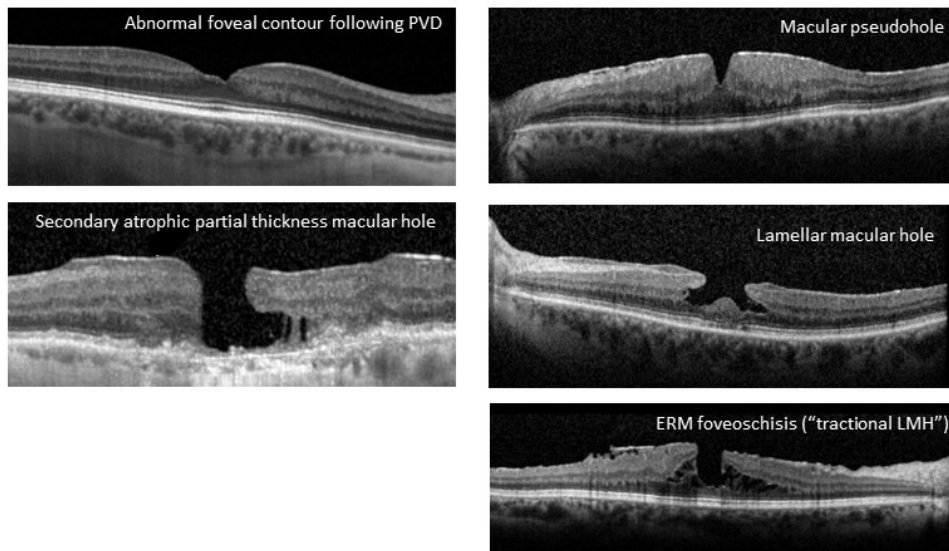
5. Classification

- a. How should macular holes be classified?
- b. What factors affect treatment choice and outcomes (and should be noted at baseline)?
(Vitreotomy, Ocriplasmin, expansile gas)

5a. How should macular holes be classified?

Macular holes are foveal defects that can be detected clinically or through optical coherence tomography (OCT). They can be further divided into partial thickness (including atrophic, those associated with epiretinal membrane including pseudoholes/ERM foveoschisis, and lamellar holes) and full-thickness macular holes (FTMH). Although fundoscopically it can be difficult to differentiate, OCT imaging shows distinct differences between these entities, and the vision is typically worse in FTMH. (Figure 6)

Figure 6: Examples of partial thickness holes. Note in all cases the neurosensory retina has continuity across the RPE.



Pseudoholes and ERM foveoschisis are associated with epiretinal membranes exerting tractional forces, causing either a steepening of foveal edge (pseudomacular hole) or a schitic change in the central retina (ERM foveoschisis) but no loss of retinal tissues.⁹⁷

Lamellar holes are characterised by an irregular foveal contour, intraretinal schisis, cavitation with apparent tissue loss and overhanging hole edges, and often associated with outer retinal loss and epiretinal proliferation.⁹⁷

FTMHs are defined as a full thickness foveal discontinuity from the internal limiting membrane (ILM) to retinal pigment epithelium (RPE) layer, with complete communication between the vitreous cavity and the subretinal space.

FTMHs can either be idiopathic secondary to age related changes in the vitreomacular interface or secondary, secondary to a range of conditions including high myopia, retinal detachment, trauma and various syndromes including Allport's syndrome. Only iFTMH are considered in this guideline.

Gass first described 4 distinctive stages of development of iFTMH in 1988⁹⁸ and later updated these in 1995.⁸⁰ This biomicroscopic classification has since been widely used clinically and in research studies. Table 1 shows a simplified Gass macular hole staging. With the advancement in OCT imaging technology, the vitreomacular interface can be studied in greater detail giving rise to better understanding of various vitreomacular disorders. Chan et al.⁴⁴ added the concept of a stage 0 macular hole in 2004 in patients with unilateral FTMH with fellow eye of normal OCT macular appearance but attached posterior hyaloid to the foveal centre (i.e., VMA). Subsequently, a panel of vitreoretinal disease experts convened in 2013 and developed the International Vitreomacular Traction Study (IVTS) group OCT-based anatomic classification system (Table 2).⁸¹ This OCT staging has largely supplemented the Gass biomicroscopic staging system – allowing for comparison of previous published reports and future studies. Table 3 shows how the traditional biomicroscopic classification correlates with the OCT findings. The IVTS classification is now commonly used and has been shown to be effective in standardising definitions.⁹⁹ (Table 2)

Macular hole size is a particularly important subclassification as it is known to predict surgical success. Many methods of measurements using OCT have been described including base diameter, minimum diameter and height.^{85,100} Researchers have also attempted to predict surgical outcome building on these basic parameters with further derived indices such as macular hole index, hole form factor, diameter hole index and tractional hole index as well as 3D shape measures such as volume.^{101,102,103,104} However, for the purpose of measuring hole sizes according to IVTS, the horizontal minimum linear diameter (MLD) is used which is measured at the narrowest hole point in the mid retina using the slice with the maximum dimensions.⁴⁴ This has been the most widely used measurement both clinically and in research, and it has been shown to have strong associations with anatomical and visual outcomes. (Figure 3)

The 400 µm cut-off used to define large macular holes in both Gass and IVTS classifications were due to numerous studies showing increased anatomical closure rates in stage 2 macular holes (<400 µm) compared to larger ones following surgery.^{84,105,106,107,108} However, this cut-off has lately been contended with newer studies showing surgical success remains high for holes larger than 400 µm, likely attributed to evolving surgical techniques employed resulting in better closure rates in these larger holes. Some retrospective studies have found excellent surgical prognosis in FTMH up to 500 µm.^{109,110} A large UK database study of over 1483 eyes with macular holes similarly showed surgical success rate only starts to decline when the MLD exceeds 500 µm in size, to 90% or less.⁸⁶ Another retrospective case series¹¹¹ suggested a higher, second cut-off of 630 µm where closure rates reduced again.¹¹² Recently, the CLOSE Study Group (Classification for Large Macular Hole Studies) consisting of expert vitreoretinal surgeons in the field of macular hole surgical treatment conducted a systematic review aiming to reclassify large macular holes.¹¹³ They proposed further subclassifying large macular holes to Large (> 400 to ≤ 550 µm), X-Large (> 550 to ≤ 800 µm), XX-Large (> 800 to ≤ 1000 µm) and Giant (> 1000 µm). However, there was heterogeneity in the aetiology as this study included patients with primary, secondary and refractory macular holes.

Table 1: Adapted from Gass’s macular hole staging⁹⁸

Gass Staging	Biomicroscopic Findings	Anatomic Interpretation
1-A (impending hole)	Central yellow spot	Early serous detachment of foveolar retina
1-B (occult hole)	Yellow ring with bridging interface	Serous detachment of foveolar retina
2	Retinal defect < 400 µm inside yellow ring	FTMH < 400 µm
3	Central round retinal defect ≥ 400 µm with no Weiss’s ring	FTMH ≥ 400 µm with no PVD
4	Central round retinal defect (any size) with Weiss’s ring	FTMH (any size) with complete PVD from optic disc and macula

FTMH = full-thickness macular hole; PVD = posterior vitreous detachment

Table 2: Adapted from Duker et al.⁸¹

IVTS Classification	Description	Subclassification
VMA	<ul style="list-style-type: none"> • Perifoveal vitreous cortex detachment from retinal surface • Macular attachment of the vitreous cortex within 3-mm radius of fovea • No detectable change in foveal contour/retinal tissues 	<ul style="list-style-type: none"> • Size of attachment <ul style="list-style-type: none"> • Focal (≤1500 µm) • Broad (>1500 µm) • Isolated or concurrent retinal conditions
VMT	<ul style="list-style-type: none"> • Perifoveal vitreous cortex detachment from retinal surface • Macular attachment of the vitreous cortex within 3-mm radius of fovea • Distortion of foveal surface, intraretinal structural changes, and/or elevation of fovea above RPE without full-thickness interruption of all retinal layers 	<ul style="list-style-type: none"> • As above
FTMH	<ul style="list-style-type: none"> • Full thickness foveal lesion that interrupts all macular layers from the ILM to RPE 	<ul style="list-style-type: none"> • Size (MLD) <ul style="list-style-type: none"> • Small (≤250 µm) • Medium (>250 µm and ≤400 µm) • Large (>400 µm) • Presence or absence of VMT • Primary or secondary causes

FTMH = full-thickness macular hole; ILM = internal limiting membrane; MLD = minimum linear diameter; RPE = retinal pigment epithelium; VMA = vitreomacular adhesion; VMT = vitreomacular traction

Table 3: Correlation between biomicroscopic and OCT classification (adapted from Duker et al.)⁸¹

Modified Gass's Classification	IVTS Classification
Stage 0	VMA
Stage 1 (impending macular hole)	VMT
Stage 2 (small FTMH)	Small (<250 microns in MLD) or medium (250-400 microns in MLD) FTMH with VMT
Stage 3 (large FTMH)	Large (>400 microns in MLD) FTMH with VMT
Stage 4 (FTMH with complete PVD with separation of vitreous from optic disc head)	Small, medium, or large FTMH without VMT

FTMH = full-thickness macular hole; PVD = posterior vitreous detachment; VMA = vitreomacular adhesion; VMT = vitreomacular traction

5b. What factors affect treatment choice (vitrectomy, ocriplasmin, expansile gas) and outcomes and should be noted at baseline?

The main factor that affects treatment option and outcomes of macular hole is the size, and in particular MLD,^{85,114} which directly correlates to the different Gass stages as well as the IVTS classification. Other important factors of prognostic importance include presenting visual acuity and duration of symptoms. Better baseline visual acuity and shorter duration of symptoms have been shown to be associated with higher closure rates and better post-operative visual acuity.^{93,108} Presence of VMT and ERM would also affect the treatment option of intravitreal Ocriplasmin.

Four main treatment options have been described – observation, intravitreal expansile gas injection (pneumatic vitreolysis), intravitreal Ocriplasmin and vitrectomy. (See Section 6a)

Summary

Both Gass's biomicroscopic classification and IVTS OCT classification can be used to complement each other in clinical practice.

With development in surgical techniques, closure rates in large macular holes are expected to continue to improve. The cut-off of 400 µm for large macular holes should be retained, but there is the potential for further subclassification, particularly based on an approximate 500 microns size threshold.

MLD should be used to measure hole sizes due to its practicality and strong association to surgical outcomes. It is also the most widely accepted measurement in research practice, allowing for comparisons among studies. Therefore, it is important to select an accurate OCT slice which represents the true extent of the macular hole with its maximum dimensions when measuring MLD, either using radial scans or high-density horizontal scans through the hole.

Important baseline factors to consider are macular hole size/MLD, presenting visual acuity, duration of symptoms, as well as presence of VMT and ERM. Treatment options are mainly based on macular hole size.

6. Different Management Options

Background

The management options proposed for iFTMH are observation, intravitreal ocriplasmin, and pars plana vitrectomy with intravitreal gas tamponade, often with internal limiting membrane (ILM) peeling. A less commonly used approach is pneumatic vitreolysis. Each management option is considered below.

Observation

Observation, either in a hospital clinic or optometry setting, may be appropriate for patients who do not want intervention, or those hoping that their hole will close spontaneously. It is thought that spontaneous closure is more likely for small stage 2 iFTMHs of short duration or following spontaneous release of vitreomacular adhesion (VMA), and less likely for longstanding, large, stage 3 or 4 iFTMHs, and those that persist despite VMA release.^{86,93,106,116,117,118,119,120,121,122}

A 2016 UK vitreoretinal practice survey (response rate ~50% of UK surgeons) indicated that 25% of respondents would advise a period of observation for patients presenting with a symptomatic 235 µm macular hole with persisting vitreomacular traction (VMT).⁹⁶ If waiting leads to an iFTMH closing spontaneously then that avoids the downsides of surgery, but spontaneous resolution is relatively uncommon for stage 2-4 holes (unlike for stage 1 holes, where resolution is much more likely).¹²³

In a prospective study of 122 participants with iFTMH undertaken prior to the introduction of OCT, participants were grouped into three categories based on the duration of follow up: 1-3 years'; 4-5 years'; and at least 6 years' follow up. Only three of the 25 participants in the ≥6-year group had resolution, with none resolving in the other two groups, suggesting an overall resolution rate of only 2.5% (3 of 122 participants). During the period of observation, visual acuity reduced by at least two lines in 45%, with 27.9% losing at least three lines.¹²⁴ In an observational pre-OCT series of 97 patients with an average follow up of 66 months, spontaneous resolution occurred in six eyes (6.2%).¹²⁵ In another pre-OCT series of 66 eyes with stage 3 holes and mean follow up of 4.7 years, three cases (4.5%) resolved.¹²³

A Cochrane review⁹¹ of macular hole surgery versus observation included three randomised controlled trials (RCTs) published between 1996 and 2004, pre-OCT, and found that 11% of the stage 2 to 4 holes closed in follow-up ranging from 6-12 months.^{106,114,121,122} In one of the included studies, comprising only stage 2 holes, three of 19 eyes (15.8%) closed, but 14 (74%) progressed to stage 3 or 4 over 12 months.¹²² A related study by the same group included only participants with stage 3 or 4 holes, and closure occurred in two of 56 (3.6%) eyes by 6 months.¹⁰⁶ The third study included a mix of stage 2 (39.3%), 3 (45.9%) and 4 (14.8%) holes and reported that seven of 61 (11.5%) holes closed; six within 3 months and one more between 3 and 12 months.¹¹⁴

The most relevant data in the OCT era came from randomised controlled trials (RCTs) of ocriplasmin for the treatment of symptomatic VMT. The studies included participants with both VMT and iFTMH. Of 47 MHs in the control group of two related studies, 10.6% had OCT-confirmed MH resolution within 28 days of an intravitreal saline injection, increasing to 17.0% by 6 months^{118,119}. Just over half (53.2%) of the MHs were ≤250 µm diameter. None of the 19 holes greater than 400 µm closed. It is possible that a sham injection increases the chance of hole closure if it alters VMA, but in a subsequent ocriplasmin RCT using a sham control (no intravitreal injection), four of 26 (15.4%) control participants had resolution by month 3, with no further cases resolving thereafter.¹²⁶ The closure rates in this small sample were 27.3% (three of 11 eyes) in holes ≤250µm, 9.1% (one of 11 eyes) for MHs 250-400 µm, and none of the four MHs >400 µm resolved spontaneously.

Question 6.1: What is the probability of spontaneous iFTMH closure with observation?

The rate of spontaneous closure ranges from 2.5% to 27% depending on size and duration of the hole and the method of imaging.

GRADE Low; SIGN Grade C (References A-G) ^{124, 125, 123, 91, 118, 119, 120}

The reported rate of spontaneous iFTMH closure ranges from a minimum of 2.5% over 1-6 years' follow-up in one pre-OCT natural history study (GRADE 2+)¹²⁴ up to 27% after 6 months' follow-up in the control group of an OCT-era RCT (Grade 1+)^{118,119}. The size and duration of the hole most likely influence its chance of closure.^{86,93,106,116,117,118,119,120,121,122}

The larger natural history studies and the three RCTs included in a Cochrane review were all conducted prior to the introduction of OCT, so the observations may be less robust than currently. An extended natural history study would now probably be considered unethical, as practice surveys indicate that most patients are advised to undergo treatment and delayed treatment may adversely affect outcome. The ocriplasmin RCT data included OCT image analysis by a masked reading centre, and that increases the reliability of the assessment and reduces the risk of observation bias, but the trial populations only included participants with VMT and most had small holes, so the results may not be generalisable to other iFTMHs. Also, the RCTs were designed to assess the safety and efficacy of ocriplasmin and not as natural history studies, the most relevant analyses were post-hoc subgroup analyses (with a risk of reporting and publication bias), and there were very low numbers in the relevant control subgroup, so there is less confidence in the point estimates of hole closure rates. Also, the closure rates vary considerably across the available studies, pointing to a lack of consistency.

Pars plana vitrectomy and intravitreal tamponade

Pars plana vitrectomy and intravitreal gas tamponade is the standard approach for iFTMHs, often in association with internal limiting membrane (ILM) peel (See Section 6e)⁹⁶. Pars plana vitrectomy is undertaken using a range of different port and instrument sizes, from 20 to 27 gauge (see Section 6b). A fluid-air exchange is usually followed by an air-gas exchange, wherein the air is replaced by an isovolumetric (or near isovolumetric) injection of a perfluorocarbon gas. A 2018 UK vitreoretinal practice survey (with a response rate of ~75% of UK surgeons) found that the most commonly used intravitreal gas for a stage 2 hole <400 µm was C₂F₆ (47%), followed by SF₆ (33%), C₃F₈ (19%) and occasionally air (1%),⁹⁶ with the relative merits of each considered in Section 6f. Patients may or may not be advised to posture after surgery, to float the gas bubble onto the iFTMH and encourage hole closure. In the same 2018 practice survey, 82% of respondents advised postoperative head positioning for a stage 2 hole <400 µm, with periods ranging from 1 day (19%), to 2-4 days (30%), 5-6 days (23%) and 1 week or more (9%).⁹⁶ The evidence in support of posturing is considered in Section 6d. Vitrectomy may be combined with phacoemulsification and intraocular lens implantation (see Section 6g).

As vitrectomy is now the standard of care for iFTMH there are no recent RCTs versus observation, as such a study would most likely be considered unethical. However, a 2015 Cochrane review⁹¹ undertook a meta-analysis of three early RCTs comparing vitrectomy and observation, for participants with VA less than 6/15.^{106,114,121} The meta-analysis included one US multicentre RCT published in 1996 that randomised 42 eyes with stage 2 FTMHs, another related RCT by the same group, published in 1997, that randomised 129 eyes with stage 3 and 4 holes, and lastly a single centre, single surgeon UK RCT published in 2004, that randomised 185 eyes with stage 2, 3 and 4 holes.

At 6 to 12 months, visual acuity (VA) in the surgical group was -0.16 logarithm of the minimum angle of resolution (logMAR) superior to observation (95% confidence interval [95%CI] -0.23 to -0.09, n 270). The chance of hole closure was greatly increased with vitrectomy versus observation (odds ratio 31.4, 95%CI 14.9 to 66.3). There was benefit for all stages of hole, with an overall surgical closure rate of 79.6%. Retinal detachment occurred in 5% of operated eyes, but this rate reflects surgeries

undertaken before the introduction of small gauge surgery, which is now the standard approach. The main identified sources of bias were thought to emanate from VA testing of unmasked participants in all three studies, which is unavoidable as it is not possible to mask surgery (performance bias). Other sources of bias included unmasked VA assessors in two studies (detection bias),^{106,114} and unmasked assessment of hole closure in one study (detection bias).¹¹⁴ Using the GRADE system, the authors concluded that the quality of the evidence for VA outcome at 6-12 months was 'moderate', and the quality of evidence for hole closure was 'high'.

A recent meta-analysis combined the individual participant data from 12 RCTs, with a pooled estimate of anatomic and functional outcomes from 940 participants undergoing iFTMH surgery (H).⁹³ The studies compared a variety of surgical techniques, such surgery with or without ILM peeling, but all included pars plana vitrectomy and gas or air tamponade. The studies were published from 2005 to 2020, passing into the OCT era. The median age of the patients was 68 years, the median hole diameter 492 µm, and mean preoperative VA was 0.84 logMAR (Snellen equivalent 6/41). Primary hole closure occurred in 81.5%. At 6 months after surgery the mean VA had improved to 0.5 logMAR (6/19, interquartile range [IQR] 0.3-0.78).

Two large UK database studies have investigated the real-world outcomes of iFTMH surgery. The first (I)¹²⁷ was published in 2013 and included 1,078 eyes undergoing primary macular hole surgery. The median presenting logMAR VA of 0.80 (6/38) improved to 0.5 (6/19) after surgery, with 57.8% of eyes gaining at least 0.3 logMAR (approximately 2 Snellen lines). Repeat macular hole surgery was undertaken in 4.2%, indicating a maximum anatomic success of 95.2%, but likely lower, as not all patients will have elected to undergo repeat surgery if their hole failed to close with primary surgery. Complications included 2.4% undergoing retinal detachment surgery, and 64.6% of phakic eyes undergoing cataract surgery within a year. The second UK database study (J),⁸⁶ published in 2021, included 1,483 primary macular hole surgeries. In the 1,253 operations (84.5%) with known anatomic outcome, holes closed in 95.7%. The median presenting logMAR VA was 0.78 (6/36), improving to 0.42 (6/16) post-operatively, with 64.2% gaining at least 0.3 logMAR.

The reason for the difference in database versus RCT outcomes is not certain but may result from differences in case mix (trials have varying levels of selectivity), reporting bias (clinicians may be anxious about sharing poor results within a database study, but have little flexibility to exclude outcomes within a monitored RCT), and incomplete data (a common issue within database studies).

Question 6.2: Is pars plana vitrectomy and intravitreal tamponade a safe and effective treatment for iFTMH?

Vitrectomy is an effective treatment for iFTMH, with risks that are well characterised and generally acceptable.

85% or more people with stage 2-4 iFTMH would be expected to have anatomical success (macular hole closure) following primary surgical repair (one vitrectomy) and improve around 15 ETDRS letters, although both, anatomical and functional outcomes depend on the size of hole and presenting vision as well as duration the hole has been present for prior to treatment.

GRADE High; SIGN Grade A^{86,91,93,127}

All the sources of evidence appraised indicate that the benefits of vitrectomy and tamponade outweigh the risks, for most patients with iFTMH, both in terms of VA and hole closure. The RCTs against natural history were undertaken a long time ago, but the Cochrane review of these early studies indicates that surgery offers logMAR acuity that is -0.16 superior to observation. The results are likely to be even better now, with refinements to surgical technique.

Although not compared to natural history, the individual participant data meta-analysis showed a closure rate of 81.5%, with clinically and statistically significant VA gains at 6 months. The two large database studies reported noticeably higher closure rates. This may reflect advances in surgical

technique; however, bias cannot be easily excluded. There are risks to surgery, including cataract in a majority of phakic patients, but these are well characterised.

Ocriplasmin

Ocriplasmin is a truncated form of human plasmin produced by recombinant DNA technology in a yeast (*Pichia pastoris*) expression system.¹²⁸ It is a serine protease with proteolytic activity against key constituents of the vitreous and vitreomacular interface, including laminin, fibronectin and collagen. 128 Ocriplasmin aims to loosen and release VMA, which is often termed enzymatic vitreolysis. It is marketed in Europe by Inceptua as Jetrea®, licensed for the treatment adults with of vitreomacular traction (VMT), including when associated with macular hole of diameter $\leq 400 \mu\text{m}$.¹²⁸ (145) It is currently not marketed in the UK but is available in some other countries. Recommendations for treatment in the UK are therefore not given in this guideline. It is not suitable for cases where VMA has already released, and a pre-specified subgroup analysis indicated that the success rate diminishes if there is also an ERM.¹¹⁵

National Institute for Health and Care Excellence (NICE) guidance recommends ocriplasmin as an option for the treatment of VMT in adults only if:

- an epiretinal membrane is not present
- and
- patients have a stage 2 full-thickness macular hole with a diameter of $400 \mu\text{m}$ or less and/or
 - they have severe symptoms.

Ocriplasmin is administered as a single pars plana, intravitreal injection containing 0.125 mcg in 0.1 mL. If ocriplasmin is to release VMT it usually does so within 28 days of injection, but if not, patients can proceed to iFTMH surgery.¹¹⁵

A Cochrane review (K)¹³⁰ considered the use of ocriplasmin for the treatment of symptomatic VMT, to include both VMT and iFTMH with persisting VMT. The review included four US and European RCTs comparing ocriplasmin versus sham injection or intravitreal placebo injection of vehicle/saline. A total of 932 eyes were included, all with OCT-confirmed symptomatic VMA, and VA of at least 6/7.5, of whom 229 had iFTMH. The trials included the phase 2 MIVI-IIT RCT (n 60; published in 2010; L),¹³¹ two related phase 3 registration RCTs, TG-MV-006 and TG-MV-007, that were analysed together and often referred to collectively as the MIVI-TRUST trial (n 652; 2012; M),¹¹⁵ and the phase 3b OASIS study (n 220; 2016; N),¹²⁰ which had two year follow up and excluded participants with epiretinal membrane. All except the smallest study, MIVI-IIT, excluded participants whose iFTMH was greater than $400 \mu\text{m}$, with 44.7% of MHs $\leq 250 \mu\text{m}$ in diameter, 36.8% $251-400 \mu\text{m}$, and 18.4% $>400 \mu\text{m}$. The main outcomes were assessed at 28 days and 6 months.

Compared to control, ocriplasmin treatment resulted in a greater likelihood of iFTMH closure, with a risk ratio of 2.87 (95%CI 1.50 to 5.51); 12.3% of participants had hole closure without treatment, versus 35.4% with ocriplasmin (95%CI of difference between groups: 6.2% to 55.6%). This result was thought to have a high certainty of evidence using GRADE.

Ocular adverse events were more common in the ocriplasmin treated participants, occurring in 69.7% versus 57.1% (risk ratio 1.22; 95% CI 1.09 to 1.37), based on 909 eyes in the four studies of both VMT and iFTMH. The increased adverse event rate was driven by a greater incidence of vitreous floaters, photopsia, injection-related pain, blurred vision, visual impairment, and conjunctival haemorrhage. Retinal tears and cataract were no more likely in the ocriplasmin group. The safety data were deemed to have a moderate certainty of evidence using GRADE.

A more recent systematic review and meta-analysis of the use of ocriplasmin, for the treatment of both VMT and iFTMH with VMT (n =1,0670, O),¹³² included the same studies incorporated in the Cochrane

review, plus a Japanese randomised double-masked sham-controlled trial of 172 participants. Unlike the Cochrane review, it included individual participant data. About a quarter of the combined population had iFTMH.

The chance of iFTMH closure with ocriplasmin was 36.8% versus 9.3% in the control group, with an adjusted odds ratio of 6.1, favouring ocriplasmin (95%CI 2.7 to 13.7). In the iFTMH group, the unadjusted incidence of vitrectomy was 53.4%, versus 72.0% in the control group (odds ratio 0.49, 95% CI 0.28 to 0.87)

In those with iFTMH the mean VA change from baseline favoured the ocriplasmin-treated group with a gain of 5.97 letters, versus 3.33 letters in the control group, with a mean adjusted difference between groups of 2.32 letters (95%CI of difference between groups, 0 to 4.63). The chance of gaining at least 10 letters was greater in the ocriplasmin group, but the confidence interval included 1 so it is not certain that there is a difference (odds ratio 1.49, 95%CI 0.87 to 2.56). The chance of losing at least 10 letters was lower the ocriplasmin group, but the confidence interval also included 1 (odds ratio 0.43, 95%CI 0.15 to 1.25).

Heterogeneity was low. Overall, the risk of bias was considered low, both for hole closure and VA changes.

Considering the VMT and iFTMH groups combined, adverse events that occurred more commonly in the ocriplasmin-treated participants were floaters, photopsia, photophobia, eye pain, blurred vision and visual impairment. Short-term visual impairment, usually within the first week, was more common in the ocriplasmin group (25.1% versus 12.4%) but was not predictive of final VA. Usually transient dyschromatopsia occurred in 4.5% of the ocriplasmin group versus 0.6% of controls. Retinal detachment occurred in 1.9% of the ocriplasmin group and 1.2% of the control group.

In the iFTMH subgroup, iFTMH progression occurred in 25% of ocriplasmin treated participants versus 18.4% of controls. A case of photoreceptor toxicity was reported in a patient with iFTMH, occurring 6 days after dosing, and manifesting as subjectively dimmed vision, floaters and nyctalopia. Examination findings included reduced colour vision, iritis and enlarged iFTMH. The patient underwent vitrectomy, after which there was retinal degeneration, retinal artery stenosis and retinal haemorrhage, with VA reduced from 57 to 50 letters, but by year 2 VA had improved to 70 letters.

The OASIS study provided a breakdown of VA outcomes in those with and without iFTMH. The mean VA gain in the ocriplasmin group was +12.2 letters, with 40% gaining at least 3 lines. The vision outcomes were not significantly different to controls, albeit with fewer participants needing vitrectomy to achieve these gains.

Despite positive primary outcomes from the above studies, versus sham/placebo, the adoption of ocriplasmin has been poor. A 2016 UK practice surveys indicated that 6% of respondents would advise ocriplasmin to treat a 235 µm macular hole with persisting VMT,⁹⁶ but it is likely that usage has declined since. One reason may be the drug cost, which exceeds the NHS tariff for vitrectomy,¹³³ and cost modelling that suggests vitrectomy is a cheaper primary therapy.¹³⁴ Also, ocriplasmin has a lower anatomic success rate than vitrectomy, albeit without the downsides of surgery.

Another reason was concerns¹³⁵ that real world safety events are more prevalent, different, or more severe than those observed in the MIVI-TRUST RCTs.¹¹⁵ Concerns emerged in a series of case reports or small case series, which detailed adverse events attributed to ocriplasmin treatment, including subjective and objective reduction in vision, visual field loss, dyschromatopsia, abnormal pupillary responses, hole enlargement, reduced RPE adhesion, ellipsoid defects and electroretinography abnormalities. However, determining the adverse event rates from case reports and small case series is difficult due to an unknown denominator (number of ocriplasmin treatments), potential under or over reporting, and reporting and publication bias (it is less likely that clinicians will report, and journals will publish, uneventful treatments).

Perhaps, because of these safety concerns, the OASIS study included an ERG sub-study, undertaken on 40 participants in the ocriplasmin treatment group and 21 in the sham control group. In the ocriplasmin

group, 16 (40%) had reduced ERG amplitude, versus one in the sham group (4.8%). The ERG alterations resolved by study end in 13 (81.3%) of the ocriplasmin group and the one control participant. OASIS also investigated ellipsoid defects in the central 1 mm zone, via a masked, independent reading centre analysis of all available OCT images. At month 24, 25 of 108 (23.1%) participants in the ocriplasmin group and 17 of 42 (40.5%) in the sham group had discontinuity in the central ellipsoid line. The Roth 28-hue test was used to look for dyschromatopsia, with abnormality reported in 42 of 146 (28.8%) participants in the ocriplasmin group, and 14 of 74 (18.9%) in the sham group.

A UK study by the British and Eire Association of Vitreoretinal Surgeons (BEAVRS) attempted to address uncertainty about ocriplasmin safety via a members' survey.¹⁴⁴ All BEAVRS members with a registered email address were contacted electronically in October 2014, requesting information on cases treated with ocriplasmin. Respondents were asked to comment on the occurrence of various adverse events described in the MIVI-TRUST study, and others identified subsequently, including dyschromatopsia, ellipsoid changes, ERG changes, increased basal hole diameter and zonular instability. Of 173 members contacted, 48 (27.7%) responded, reporting results from 241 eyes. Retinal detachments occurred in 3.3% of the BEAVRS cohort, versus 0.4% who developed a retinal detachment prior to any surgery in MIVI-TRUST. Of the complications not identified in the MIVI-TRUST trials, there was increased iFTMH basal diameter (in those without hole closure) in 46.9% and zonular instability at the time of cataract surgery in 2.4%. Efficacy was lower than MIVI-TRUST, with small (<250 µm) hole closure in 42.1% versus 58.3% (not significant), reducing to 12.7% vs 36.7% for medium (250–400 µm) macular holes (p = 0.01).

Question 6.3: Is ocriplasmin effective at closing iFTMHs?

Compared to placebo or sham, ocriplasmin is effective in closing iFTMH less than 400 microns with VMT with closure rates in approximately 35% of cases.

GRADE High; SIGN Grade A^{115,120,130,131,132}

There are four relevant RCTs that consider the rate of iFTMH closure, graded as 1+, 1++, 1++, and 1++, and two meta-analyses (both 1++). The Cochrane review (1++) and individual participant data meta-analysis (1++) indicate that ocriplasmin is associated with iFTMHs closure in 35.4% to 36.8% of participants, but this applies only to those with persisting VMA, and was based on a trial population comprised mainly of small or medium holes (<400µm), so results can only be generalised to this population. Results are worse if epiretinal membrane co-exists.

To determine the level of evidence as High, and the recommendation as Strong, the GRADE system requires that there is at least one meta-analysis or RCT rated as 1++, directly applicable to the target population, with overall consistency of results. Notwithstanding the important debate in the vitreoretinal community about the relative merits of ocriplasmin, these criteria have been met in the four RCTs and two meta-analyses.

Question 6.4: Is ocriplasmin effective at improving visual acuity?

Ocriplasmin is effective at improving distance visual acuity by approximately 6 letters in iFTMH.

GRADE High; SIGN Grade A^{120,130,132}

The evidence indicates that ocriplasmin is effective at improving mean VA by about 6 letters. This is statistically superior to sham or placebo, but the difference is small (about 2 letters). The analysis assumes that patients have access to vitrectomy if ocriplasmin fails to close the hole.

The estimated VA benefit is based on the individual participant data meta-analysis (1++)¹³², as that included all the relevant RCTs and reported VA results separately for the iFTMH subgroup. The recommendation is strong because there is consistency across five RCTs, graded 1+ to 1++, and two meta-analyses graded 1++.

Question 6.5: Is ocriplasmin a safe treatment for iFTMH?

A variety of side effects have been described with variable severity.

GRADE Moderate; SIGN Grade B ^{91, 132, 144}

The Cochrane (1++) and individual participant data (1++) meta-analyses indicate that there are more adverse events in the ocriplasmin than the control groups, including a greater incidence of floaters, photopsia, photophobia, eye pain, subjectively blurred vision and dyschromatopsia. Cochrane determined that the GRADE level of evidence on safety was moderate, lower than for efficacy, due to imprecision.

The BEAVRS survey (Grade 2-) offers a useful insight into real world results and suggests a materially greater incidence of adverse events than was reported in the MIVI-TRUST trials, but due to a low response rate and the high risk of bias, the results need to be interpreted with great caution. Close post-market safety surveillance remains important.

Pneumatic vitreolysis

Pneumatic vitreolysis involves an intravitreal gas injection to treat iFTMH. It is also used to release VMT. It is a novel treatment option that is not currently a standard approach, or one in common use.^{145,146,147,148,149} The aim is to introduce a gas bubble that moves within the vitreous cavity, creating vitreous traction that releases VMA and thereby closes iFTMHs. Treatment involves a single injection of an expansile intravitreal gas, most often 0.3mls 100% C₃F₈,¹⁴⁷ often alongside anterior chamber paracentesis to mitigate intraocular pressure elevation. The patient may be asked to undertake a 'drinking bird' manoeuvre, wherein they tilt their head forward and up several times daily, to move the bubble and help release VMA. It has the advantage of lower cost than ocriplasmin and being easier and simpler to deliver than vitrectomy.

An RCT of C₃F₈ pneumatic vitreolysis for VMT, and a single arm study of pneumatic vitreolysis for iFTMH, were undertaken by the DRCR Retina Network and published together (protocol AG and AH respectively).¹⁴⁶ Macular holes up to 250 µm were eligible for protocol AH, with a median of 79µm in those recruited. Eligible VA ranged from 20/25 to 20/400. Patients were excluded if they had high myopia (-8.00 dioptres or more) and untreated retinal tears, but retinal round holes were allowed, and the investigator could determine if the extent of any lattice might predispose to retinal detachment (full eligibility criteria are available at ClinicalTrial.gov, using identifier NCT03677869).

At week 24 the mean VA change from baseline in the iFTMH group was +9.2 letters (95% C, 4.3 to 14.4 letters), with 18 of 34 eyes (53%; 95% CI, 37% to 69%) gaining ≥10 letters, and 3 eyes (9%; 95%CI 3% to 23%) losing 10 letters or more. The holes closed in 10 of 35 cases receiving pneumatic vitreolysis (29%; 95%CI 16-45%), but both studies (AG and AH) were terminated early due to high rates of retinal tear (n=1) and rhegmatogenous retinal detachment (n=6) (7 of 59 eyes across both studies; 12%; 95%CI 6% to 23%), including one retinal tear (2.9%) and four retinal detachments (11.4%) in the iFTMH study.

A systematic review and meta-analysis compared pneumatic vitreolysis, ocriplasmin and vitrectomy.¹⁵⁰ It included relatively open eligibility criteria, considering not just RCTs, but also non-randomised, cohort, and retrospective studies, which the authors justified due to the paucity of high quality evidence. There were 79 eligible articles for a qualitative analysis and 10 for a quantitative analysis, including patients with both VMT and iFTMH. The iFTMH closure rate was 46% with ocriplasmin, 47.8% with pneumatic vitreolysis, and 95% with vitrectomy. Safety events across eight eligible, mostly non-comparative studies, including both iFTMH and VMT, included retinal detachment, retinal tears, vitreous haemorrhage and gas migration into the anterior chamber. In one of the included studies, comparing SF6 versus C3F8 gas tamponades, three of 57 (5.3%) participants developed a MH.¹⁵¹

Another synthesis of the literature noted that pneumatic vitreolysis resulted in MH closure in 59% of cases, but with a wide 95%CI of 12% to 100% (n=15).¹⁵²

Question 6.6: Is pneumatic vitreolysis a safe and effective treatment for iFTMH?

The available data on pneumatic vitreolysis for iFTMH is limited. Thus, pneumatic vitreolysis should not be carried out without special measures for outcome and complication monitoring.

GRADE Low; SIGN Grade C ^{146, 150}

There are no high-quality comparative trials. The aborted uncontrolled iFTMH DRCR.net study (protocol AH: Grade 2+ for efficacy and 2- for safety) suggests pneumatic vitreolysis closes iFTMHs in about 29% of cases, but with a wide 95%CI of 16% to 45%. Likewise, the risk of retinal detachment and tears is not well known, as the 12% rate across protocols AG and AH also has a wide confidence interval of 6% to 23%. Anatomic success and retinal detachment rates in the rest of the literature vary widely, but these need to be interpreted with caution, as there is a high risk of reporting, publication and other biases.

Practice points

Any period of observation of iFTMH needs to consider that this added delay may reduce the chance of both visual and anatomic success following surgery (See Section 7).^{93,153}

Studies indicate that the visual acuity tends to decline during observation,¹²⁴ hole size tends to increase^{154,155}, and presenting vision, hole size and duration of symptoms are the main determinants of anatomical and visual outcomes following vitrectomy.⁸⁶ Consequently, practice surveys indicate that most MHs proceed directly to treatment. Scanning immediately prior to vitrectomy however should be considered especially in small holes in case of spontaneous closure in the interim.

Vitrectomy is now an established and proven treatment, with well characterised risks and infrequent complications.

The use of ocriplasmin has reduced in recent years, but it remains an option for small (<250 microns) holes with persisting VMA and no epiretinal membrane. Despite high quality evidence suggesting it is more effective than sham/placebo, patients should be made aware of the known complications, and the uncertainty and debate about the safety data. Currently in the UK it is not marketed and not widely available.

There is only weak evidence indicating that pneumatic retinopexy is effective, focussing mainly on small holes with persisting VMA. Given that a key trial was abandoned due to a concern that the rate of retinal detachment was unacceptably high, patients should be made aware of the hard-to-quantify risk of retinal detachment, and that this is a novel and unproven treatment. Examination should carefully exclude any predisposing risk factors for retinal detachment prior to treatment.

Research Need

Whilst vitrectomy and gas tamponade is an established treatment, the best surgical technique remains uncertain. Hence, comparative trials that refine techniques would be beneficial. The specifics of these varying surgical options, and the related research need, are considered in later sections.

The reasons for the discrepancy between the RCT and real world ocriplasmin data is not certain, but there may not currently be sufficient interest within the vitreoretinal community to drive further large studies.

Pneumatic vitreolysis has several potential advantages, but the termination of the DRCR.net protocol AG study leaves several uncertainties. It may also make it difficult for researchers to acquire funding for an RCT, unless careful case selection can mitigate the risk of retinal detachment. Such a trial is needed prior to its widespread adoption.

7. Vitrectomy considerations

Section 7a: Vitrectomy gauge

For many years 20-gauge vitrectomy was the standard of care for routine pars plana vitrectomy. With the advent of trans-conjunctival self-sealing sutureless vitrectomy and small gauge instrumentation, there has been a rapid change in the standard of care.^{156,157} First 25-gauge, then 23-gauge, and lastly 27-gauge vitrectomy platforms were introduced. Initially, there were many surgeons who thought the 25-gauge instrumentation was not rigid enough, with some difficulty noted in the transition from 20-gauge. When Eckardt introduced the 23-gauge system,¹⁵⁸ many surgeons dissatisfied with 25-gauge adopted 23-gauge as their gauge of choice. The instrumentation was closer to a 20-gauge feel, with still the advantage of trans-conjunctival sutureless surgery. Oshima introduced 27-gauge vitrectomy in 2010, initially with the same concerns as 25-gauge of being less rigid and a difficult transition.¹⁵⁹

There is some evidence that trans-conjunctival self-sealing sutureless vitrectomy (termed collectively microincision vitrectomy surgery (MIVS) is associated with improved patient comfort postoperatively.¹⁶⁰

With time, instrumentation has improved with higher quality, more rigid construction, and higher flow vitrectomy probes. Presently, the 20-gauge platform has very limited utility in many countries.

Question 7.1: Does vitrectomy gauge size influence the visual and anatomical outcomes of surgery for iFTMH?

GRADE: LOW, SIGN Grade: C

There may be no difference in anatomical and visual outcomes between different gauge sizes.^{161,162,163}

Question 7.2: Does vitrectomy gauge size influence the level of postoperative pain after surgery for iFTMH?

GRADE: MODERATE, SIGN Grade: B

MIVS probably results in less postoperative pain than standard 20-gauge surgery.^{161,162,163}

Question 7.3: Does vitrectomy gauge size influence the risk of endophthalmitis after vitrectomy surgery?

GRADE: LOW, SIGN Grade: C

There may be a higher rate of endophthalmitis after 25g MIVS as compared to traditional sutured 20-gauge, but not 23-gauge as compared to 20-gauge. The higher rate of 25-gauge may be reduced using bevelled incisions and avoidance of leaving an eye only fluid filled.

Question 7.4: Does vitrectomy gauge size influence the risk of other complications?

GRADE: LOW, SIGN Grade: C

There may be no difference in the rate of other complications between different gauge sizes.^{161,162,163}

Summary of evidence

We found 3 RCTs and one systematic review, none of which were specific to iFTMH and including only a relatively small number of patients with iFTMH. The systematic review only included one of the 3 RCTs^{161,162,163,172} We found a small number of other retrospective series of patients comparing gauge size in patients with iFTMH and other vitreoretinal conditions.^{167,168,173,174,175,176} We found 4 systematic reviews of endophthalmitis after vitrectomy with different gauges.^{168,169,170,171}

Wimpissinger et al (A) in a RCT of 23 versus 20-gauge vitrectomy of 60 people for a variety of VR diseases found no statistically significant differences in visual acuity outcomes. The 23-gauge system did however result in a significantly higher early postoperative comfort level and less conjunctival injection (both assessed on a 4-point scale).^{161,162,163,172} Surgical time was essentially equal, with a shorter wound opening and closing time negated by a longer vitrectomy time for the 23-gauge system. Two choroidal haemorrhages and one serous choroidal detachment occurred in the 23-gauge group with none in the 20-gauge group, with no statistically significant difference.

Scholz et al (B) in a RCT of 20 versus 23-gauge vitrectomy in 103 patients with macular pucker and iFTMH found that the gain in distance vision was higher in the 23-gauge group at 3 weeks but with no difference at 6 months. The 23-gauge group had a lower risk of postoperative IOP elevation, greater patient comfort in the early postoperative period (for foreign body sensation and itching measured on visual analogue scales), and a shorter surgery time.

Nam et al (C) performed a RCT of 23 versus 25-gauge vitrectomy in 85 consecutive patients with various indications for surgery. There was no difference between the two groups other than 7/47 patients in the 23-gauge group and 3/38 patients in the 25-gauge group required suturing of the sclerotomies for leakage.

Recchia et al (D), with the American Academy of Ophthalmology, performed a literature search up until 2009 of any type of article addressing the safety and efficacy of MIVS. They found 76 articles which were mainly case series. They concluded the efficacy was comparable but with the narrow-gauge group demonstrating more rapid healing, less discomfort, but a similar incidence of adverse events to 20-gauge.

We found 4 retrospective analyses (E, F, G, H) of different vitrectomy gauges in surgery which included iFTMH. Surgical outcomes were similar but there was a suggestion that intraoperative breaks particularly around the vitrectomy entry sites were higher with 20-gauge as compared to narrower gauges, although the retinal detachment rate was unchanged. Rizzo, et al reported a retrospective series of 2432 vitrectomies performed for epiretinal membrane formation and macular hole with 20, 23 and 25g. The incidence of RD was not significantly different (p value not given), with 1.7% (31 of 1862) after 25 or 23-gauge vitrectomy versus 1.2% (7 of 570) after 20-gauge vitrectomy.

In 2010, Bahrani et al (I) in a systematic review found six large retrospective comparative cases series on the 25-gauge vitrectomy as compared to 20-gauge. They found a slightly higher rate of endophthalmitis in the 25g group but noted high heterogeneity between studies and concluded the evidence base had very low certainty. They noted several factors may confound the results including the use of air/gas, combined surgery, bevelled incision use, use of prophylactic antibiotics, postoperative hypotony and diabetes mellitus.

In 2010, Oshima et al (J) reported a retrospective, interventional, multicenter survey looking at the incidence of endophthalmitis in MIVS, versus 20-gauge. They included 27 institutions with 46,868 consecutive patients, n=29,030 20-gauge, and n=14,838 23/25-gauge. The incidence of endophthalmitis was 0.034% after 20g and 0.054% after 23/25g, with no difference between the two groups. They also performed a systematic review and added six other studies to their study, again showing no significant difference between the two groups. (n=77,956 in total; 20-gauge vitrectomy (0.030%; 95% CI, 0.012 to 0.048) as compared to 23/25-gauge (0.08%; 95%CI , 0.030 to 0.164)(P =0.207)

In 2013, Govetto et al (K) in a systematic review identified 3 small randomized and 18 nonrandomized studies that reported 68 cases of endophthalmitis in 148 643 participants. The overall OR of endophthalmitis for MIVS versus standard vitrectomy was 2.3 but with wide confidence intervals, overlapping 1 (95% CI 0.8–5.8). They found an increased risk of endophthalmitis using a micro-incisional straight approach compared with standard vitrectomy (OR, 15.1; 95% CI 2.01–179), but not for a bevelled incisional approach (OR, 0.82; 95% CI 0.23–2.28).

In 2018, Bhende et al (L) in a retrospective single centre series reported on 45 cases of endophthalmitis from 111,876 vitrectomies (70,585 20-G and 41,291 23/25g). The rate of culture positive endophthalmitis overall was 0.021% overall, 0.031% for 20G, and 0.005% for MIVS group respectively. They concluded that narrow gauge transconjunctival surgery does not increase the risk of endophthalmitis.

In 2019, Chen et al (M) reported a systematic review and meta-analysis of the incidence of endophthalmitis after vitrectomy. The systematic review found a total of 31 studies with more than 500 patients in each, reported 199 endophthalmitis cases in 363,544 participants (0.05%). The incidence of endophthalmitis after 20 G vitrectomy was 0.04% (88/229,435), compared with 0.03% (8/27,326) after 23 G and 0.11% (33/29,676) after 25 G. A metanalysis of 12 comparative studies reporting on 209,146 patients found that the incidence of endophthalmitis was higher after MIVS (23 G/25 G) compared with 20 G vitrectomy (odds ratio = 3.39, 95% CI 1.39–8.23). In a subgroup analysis, an increased risk of endophthalmitis after 25 G compared with 20 G vitrectomy (odds ratio = 4.09, 95% CI, 2.33–7.18), but not for 23 G versus 20 G (odds ratio = 1.14, 95% CI, 0.47–2.78) The authors commented on the possible confounding effects of bevelled versus straight incisions, gas versus fluid filled eyes, minimal versus more complete vitrectomy and systemic risk factors but couldn't analyse these further.

Summary and practice point

The overall level of evidence regarding whether vitrectomy gauge alters the outcomes or complication rate of vitrectomy for iFTMH is low. There is evidence that patient comfort is probably improved postoperatively with MIVS as compared to traditional sutured 20g surgery, but there is no evidence for a benefit of 27 over 25 over 23-gauge. The overall rate of endophthalmitis after vitrectomy is low. There may be evidence that endophthalmitis is higher after 25-gauge surgery than 20-gauge but not 23-gauge. This may relate to surgical technique aspects in terms of incision geometry and the use of air/gas to help seal incisions. The choice is largely based on surgeon and patient preference and availability of equipment.

Research need

It is essential that properly designed robust RCTs are undertaken to determine superiority of new technologies against existing ones to avoid the introduction of new ones that may not provide as good outcomes. These need to be designed and staged to consider learning curves and appropriate masking. The Idea/Innovation, Development, Exploration, Assessment, Long-term follow-up (IDEAL) framework should be considered.¹⁷⁷

Section 7b: ILM peeling

Background

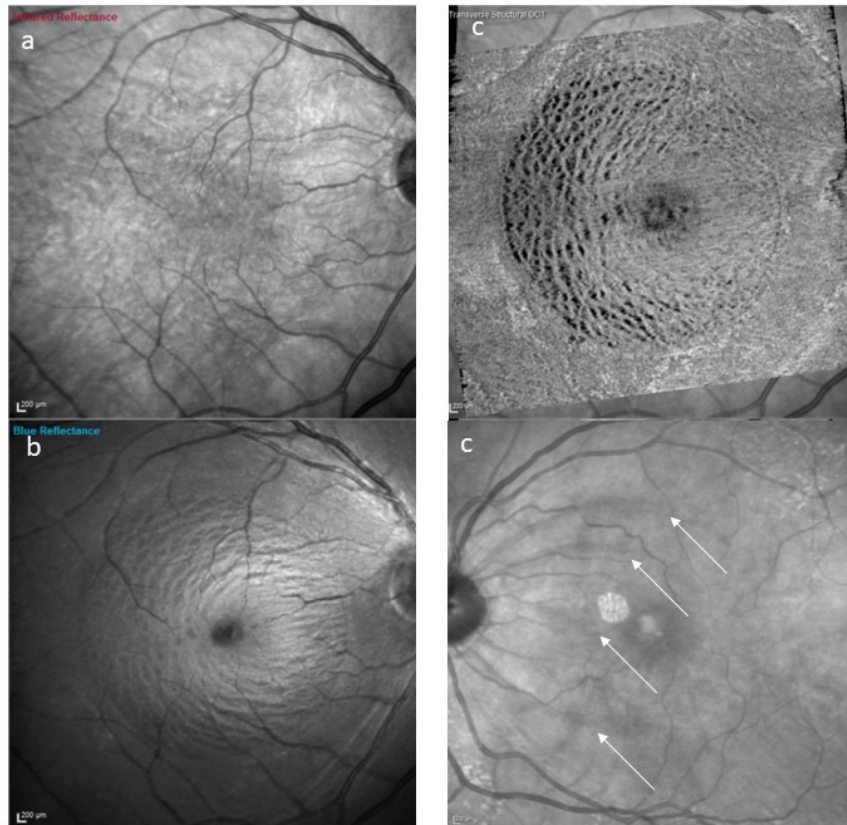
After the original description of pars plana vitrectomy (PPV) and gas tamponade to treat iFTMH in 1991, the next step in the evolution of macular hole surgery was the removal of the ILM to further improve anatomical and functional outcomes, first described by Eckardt et al in 1997.

ILM peeling is believed to aid the closure of iFTMH by various mechanisms:

1. ILM contributes significantly to retinal rigidity, and its removal increases retinal compliance aiding to the closure of the macular hole;¹⁸⁰
2. ILM may contain residual vitreous remnants after the separation of posterior hyaloid face, and may also act as a scaffold for associated fibrocellular proliferation, leading to tangential traction forces preventing hole closure,^{181,182} and
3. ILM removal may lead to retinal glial cell proliferation which may paradoxically aid macular hole closure^{180,182}

The surgical manoeuvre of ILM peeling can lead to retinal microtrauma especially as a part of the surgeon learning curve. Various retinal consequences have been described including the characteristic retinal dimpling in the ILM-peeled area of the retina called 'Dissociated Optic Nerve-Fibre Layer' (DONFL) appearance, becoming apparent 2-3 months following surgery and first reported by Tadayoni et al. after ILM peeling for ERMs.¹⁸³ This appearance is likely nerve fibre layer dehiscence rather than true nerve fibre layer defects with no consistent corresponding functional abnormalities picked up by SLO microperimetry.¹⁸⁴ Thus, its clinical relevance and impact on patients remains to be demonstrated. Similarly, SANFL has been described in the early postoperative period most visible on infrared imaging and attributed to RNFL injury at the site of forceps pick up points. (Figure 7). Focal retinal haemorrhages and nerve fibre layer defects,¹⁸⁵ thinning of the ganglion cell complex,¹⁸⁶ migration of fovea towards optic disc¹⁸⁷ and even eccentric macular holes at the site of initiation of ILM peel have been described as complications of ILM peeling.^{188,189}

Figure 7: A-C, Postoperative appearance of a dissociated optic nerve fibre layer (DONFL) after ILM peeling – note DONFL not visible on infrared imaging, clearly visible on blue reflectance imaging and even more obvious on en face imaging taken at the level of the inner retina. Dark arcuate streaks of subacute nerve fibre layer (SANFL) swelling seen within first three weeks after surgery most clearly seen on infrared imaging at sites of ILM pick up points during forceps pinch peeling.



Question 7.5: Does peeling the ILM achieve better outcomes than not peeling the ILM?

- PPV with ILM peel and gas tamponade achieves better anatomical closure of iFTMH when compared to PPV and gas tamponade without ILM peel.¹⁹⁰⁻¹⁹³

GRADE: HIGH, SIGN Grade: A

- ILM peel significantly reduces the chances of late reopening of iFTMH.¹⁹⁴

GRADE: MODERATE, SIGN Grade: B

- There is no difference in distance visual acuity between ILM peeling and non-peeling in holes which close with the initial surgery i.e., there are no detrimental effects on distance visual acuity of ILM peeling.^{190,192,193}

GRADE: HIGH, SIGN Grade: A

- ILM peel reduces the number of interventions and is cost-effective in macular hole surgery.^{192,193}

GRADE: MODERATE, SIGN Grade: B

Practice Points

ILM peel should be carried out in iFTMH of all sizes. Besides achieving a significantly better anatomical closure, the risk of late reopening of iFTMH is also reduced. With various randomised trials showing no clinically detrimental effect of ILM peeling on visual acuity and patient reported outcomes and given the higher anatomic success of the primary surgery and its cost-effectiveness, ILM peel should be considered an integral part of macular hole surgery.

Summary of evidence and comment

Anatomical Outcomes

Several randomised trials have looked at the efficacy of ILM peeling in iFTMH surgery.^{190,191,192} The full thickness macular hole and Internal Limiting Membrane Peeling Study (FILMS) was a large, UK-based, RCT looking at the outcomes of ILM peel in stages 2 and 3 of iFTMH. Anatomical closure was observed in 84% in the peel group compared to 48% in the no-ILM peel group at 1 month postoperatively ($P < 0.001$).¹⁹² Thirty-eight percent of patients randomised to non-peeling group underwent further ILM peel since the iFTMH remained open after the primary surgery. Consequently, no statistically significant difference in anatomical hole closure rates was observed at 3 and 6 months in this pragmatic RCT. A systematic review and individual participant data meta-analysis undertaken under the auspices of the Cochrane Collaboration looked at 4 RCTs in 2013 and concluded that ILM peeling compared with no peeling increases the chance for a macular hole closure (stages 2, 3 and 4) and reduces the chances of reoperations.¹⁹³

A key question is whether ILM peel should always be carried out in macular hole surgery. ILM peel may be considered necessary in large (>400 microns) and chronic (>12 months) macular holes, but its role in iFTMH less than 250 microns has been debated. Tadayoni et al in a retrospective study found a success of 100% in both ILM peel and no-peel groups with FTMH <400 microns. Only 15 and 18 iFTMH were included in peel and no peel groups, respectively, with <400 microns so the evidence is not robust.¹⁹⁶ It should also be noted that the authors used 17% C2F6 gas tamponade and 10 days of face-down posturing even for FTMH <400 microns. Furthermore, ERM peeling was undertaken, if present, and accidental removal of the ILM when peeling ERMs can occur. In smaller macular holes, anteroposterior traction by vitreomacular adhesion may have a bigger role to play than the tangential traction caused by the ILM. Release of this traction by PPV alone without ILM peeling works in a similar way to spontaneous hole closure after release of vitreomacular traction or macular hole closure by expansile gas or ocriplasmin. Hole shape may potentially be a factor in determining the necessity for ILM peeling. Rectangular macular holes with a small difference between MLD and base diameter (i.e narrow width factor) have a higher closure rate with Ocriplasmin treatment compared to triangular macular holes with a larger basal width. It can be postulated that such cases may also have a high success rate with PPV alone without ILM peel. However, the RCTs clearly establish the necessity for ILM peel in iFTMH of all sizes.^{190,191,192}

Additionally, not peeling the ILM may increase the chance for late reopening of the macular hole. A meta-analysis of 5480 macular hole surgeries amongst 50 publications reported that the iFTMH reopening rate was 7.12% in patients without ILM peeling as against 1.18% with ILM peeling (odds ratio: 0.16; 95% confidence interval: 0.11-0.22; Fisher's exact test: $P < 0.0001$), concluding that ILM peeling during PPV for iFTMH reduces the likelihood for macular hole reopening.¹⁹⁴

Functional Outcomes and retinal consequences of ILM peeling

Some studies have reported microscotomas and reduced retinal sensitivity after ILM peeling.^{198,199} More importantly, the visual acuity in large RCTs like FILMS did not report any statistically significant differences in distance visual acuity between ILM peel and no-peel group at 6 months.¹⁹² These results were based on intention-to-treat principle, and did not take into account the need for repeat surgery with ILM peel in the persistently open macular holes i.e. patients who failed primary surgery in the no-peel group went on to have ILM peel before the designated end-point at 6 months where visual acuity (the primary outcome) was assessed. There was evidence though of improved distance visual acuity at 3 months in the ILM peeling group.¹⁹³ Christensen et al looked at visual outcomes in primary hole closure to truly determine the effect of ILM peeling (including dyes used to stain the ILM) on the functional outcomes of PPV for iFTMH.¹⁹⁰ There was a trend towards better mean BCVA in non-peel group in stage 2 iFTMH compared to ILM peel group, although there was no difference in stage 3 holes. Overall, the eyes with the primary hole closure achieved a significantly better vision compared to those eyes that required a second surgery to achieve anatomical success. Hence, any potential functional benefit of not peeling the ILM is offset by the increased risk of failure and the need for further surgery. Furthermore, an analysis of eyes with primary closure in an IPD analysis of 3 RCTs on ILM peeling showed no significant difference in visual acuity i.e. not peeling the ILM did not improve visual acuity even in those with primary closure (n=143, mean difference in logMAR visual acuity 0.04(95% CI -0.05-+0.13)) (personal communication).

E. ILM peeling techniques

Background

Vitreotomy with internal limiting membrane (ILM) peel and intravitreal gas tamponade is the standard surgical technique for iFTMH with anatomical closure rates reported to be as high as 85-100%.^{192,193,200,201,202,203}

The ILM is the thin and translucent innermost layer of the retina, responsible for at least 50% of retinal rigidity.¹⁸⁰ A number of surgical techniques, dyes and instruments have been developed to aid in its identification and removal without collateral retinal damage.²⁰⁴

ILM Peel

a) Staining of ILM

After removal of vitreous, the first step in the process of ILM peeling is the staining of the ILM. Given that the ILM is transparent and microns only in thickness, the visualisation of this inner retina layer can be achieved by using adjuvant dyes. There are various adjuvants that can be used for this purpose, including indocyanine green (ICG), trypan blue (TB) and brilliant blue G (BBG). Triamcinolone acetonide, albeit not a dye per se, has also been used for this purpose. Triamcinolone crystals adhere to the ILM as white specks, and when removed with the ILM, create a contrast between the peeled and non-peeled retina.²⁰⁵

ICG has a strong affinity for ILM and was the initial dye used specifically to stain the ILM.²⁰⁶ It has the great advantage of apparently part 'detaching' the ILM from the retinal surface, facilitating its removal. Subsequently, concerns were raised about its potential toxicity, with some reports identifying inner retinal and optic nerve damage, visual field defects and poor visual acuity outcomes.^{207,208,209} Although the evidence for ICG toxicity is not absolute, the use of ICG has faded away. If used, it would be recommended to use it in a low concentration with minimal exposure time and illumination due to its photosensitising properties.

TB and BBG were subsequently developed and seem to have a better safety profile. TB stains both ILM and ERM, whereas BBG has a selective affinity for ILM.^{210,211}

b) ILM peel technique and instrumentation

ILM peel is initiated by creating an ILM flap safely, and a variety of instruments have been used to achieve this including picks and microvitreal blades.²⁰⁴ Initial ILM flap can also be achieved by gently scraping the ILM surface with a diamond-dusted membrane scraper or a micro-serrated nitinol loop.²¹² Frequently though, most surgeons utilise the direct 'pinch and peel' technique, where customised vitreoretinal forceps are employed to lift the ILM off the retinal surface and pull tangentially, creating an ILM flap with a rip point 180 degrees from the pull direction. Forceps design and manual dexterity are critical here to avoid trauma to underlying retinal tissue. There have been rapid improvements in forceps design, and the newer generation forceps have a large grasping platform and texturised, laser-ablated tip surface potentially allowing for a safer ILM peel.²¹³ The ideal starting point of ILM peel is debatable. ILM peel is thickest and most rigid at around 1000 microns from the foveal centre.²¹⁴ The temporal retina has a thin ILM and the nasal retina has the papillomacular bundle. The ideal starting point may be around 1000 microns directly above or below the foveola.^{204,215}

Once the ILM flap has been created, the peel can be propagated and completed using preferably vitreoretinal forceps. This part of the procedure needs to be optimised to reduce shear stress on the underlying retinal layers.

c) ILM peel size

There is no consensus on the ideal ILM peel size. Ideally there should be a customised minimum ILM peel specific to each iFTMH shape, size and chronicity, which allows for the hole to close with less consequences to the surrounding retina and visual function. Most vitreoretinal surgeons peel around 1 disc diameter (DD) of ILM from the foveal centre, although there is great variability in practice from 0.5 to 3 DD of peeled ILM.²¹⁶

Variations to standard ILM peel

Variations in the standard technique have been explored to achieve better functional and anatomical outcomes. Fovea-sparing ILM peeling is one such technique first described by Ho et al for stage 2 iFTMH where sparing the central ILM would preserve the foveal microstructure, and potentially lead to better functional outcomes.²¹⁷ Alternatively, as the size of iFTMH increases, the success of surgery with standard ILM peel reduces. The success rate of standard ILM peel surgery remains high at 90% or more for iFTMH with minimum linear diameter (MLD) of up to 500 microns before falling to less than 90% above that threshold.^{86,111}

Ch'ng et al in a retrospective study of 258 eyes with large iFTMH with MLD > 400 microns, and concluded that the anatomical success rate remained high with PPV and ILM peel above 90% for FTMH < 500 microns, dropped to less than 90% for FTMH > 500 microns, with a further inflection point of 630-650 microns, when the success rate dropped to less than 80%.¹¹¹ Another retrospective study of over 1500 eyes in a large UK prospectively collected database looked at outcomes of macular hole surgery and concluded that macular hole closure was high at over 95% until a size of around 500µm where it reduced to less than 90%.⁸⁶

Hence alternative techniques have been explored to increase success rate for large iFTMH. The surgical variation which has gained the most popularity in recent years is the inverted ILM flap technique, first described by Michalewska et al in 2010.²¹⁸ In this original description of this method, ILM is peeled for around 2DD around the iFTMH, but instead of completely removing the ILM, a remnant is left in place, attached to the margins of the macular hole. The peripheral ILM is trimmed using vitreous cutter at minimal vacuum or scissors, leaving behind about 0.5 to 1 mm of ILM frill. This ILM remnant is then inverted upside-down using forceps to cover the macular hole. Fluid-air-gas exchange is then performed as in the standard surgery. The ILM flap is believed to work by acting as a scaffold for tissue growth. The presence of Muller cell fragments on the ILM frill inside the macular hole stimulates glial cell proliferation, helping the iFTMH to close.

Since the initial description, there has been a lot of emphasis on ILM flaps for large macular holes, with various studies demonstrating success rates between 85 and 100%.^{219,220,221,222} After the original inverted flap technique description, multiple variations in how ILM flaps are created have been described. Michalewska again described the modified 'temporal' single-layered ILM flap technique where ILM was only peeled in the temporal macula and left hinged to the temporal boundary of the iFTMH.²²³ This was then folded over the macular hole as a flat sheet to achieve the same effect as the 360-degree hinged traditional ILM flap.

Question 7.6: Does the use of adjuvant dyes improve outcomes?

Staining the ILM with adjuvant dyes may improve the closure rate of macular hole surgery by allowing more complete ILM peeling.

GRADE: LOW, SIGN Grade: C

Brilliant blue G is possibly associated with an improved visual acuity outcome when compared with ICG.^{224,225}

GRADE: LOW, SIGN Grade: C

Question 7.7: Does ILM peel size effect outcomes?

A large ILM peel size (>1 disc diameter in radius) probably improves the closure rate of iFTMH over 300-400 microns in MLD.

GRADE: MODERATE, SIGN Grade: B

Question 7.8: When should adjuvant techniques to improve IFTMH closure be used?

The success of standard macular hole surgery of vitrectomy, ILM peel and gas tamponade decreases above 500-600 microns in MLD when alternative techniques should be considered.^{86,111}

GRADE: LOW, SIGN Grade: C

An inverted ILM flap technique improves the anatomical closure rate of iFTMH (>500 microns in MLD) when compared to conventional ILM peel and may improve distance visual acuity.^{218,232,233,234,235}

GRADE: MODERATE, SIGN Grade: B

Summary of evidence and comment

Staining of ILM with adjuvant dyes aids in its visualisation before ILM peeling is commenced. A study comparing ICG, TB and ICG as surgical adjuvants in macular hole surgery showed that BBG was similar to ICG in the ease of ILM peeling, and comparable to TB in optimising visual and functional outcomes; hence combining the beneficial properties of both other dyes with an excellent safety profile.²²⁴ A meta-analysis of 29 studies and 2514 eyes looking at the role of dyes in macular hole surgery concluded that the iFTMH closure after ILM peeling with dyes was better than without dyes, and the highest safety profile was with BBG followed by TB, TA and ICG in that order.²²⁵ Irrespective of the dye used, the dye concentration and the retinal contact time should be minimised to reduce potential toxicity, with contact periods as low as 5-10 seconds providing sufficient staining contrast.²³⁶

ILM peel requires customised instrumentation such as vitreoretinal forceps, diamond-dusted membrane scrapers or a micro-serrated nitinol loops. There is some evidence suggesting that DONFL appearance of the retina and cellular debris on the retinal surface of the peeled ILM may be more when a membrane scraper is used compared to ILM forceps in the initiation and completion of ILM peel.²³⁷

Five RCTs have looked at the extent of ILM peel and its impact on macular hole surgery ^{226,227,228,229,230} There were sample size concerns in these studies and variable findings. A recent individual participant data analysis of 5 RCTs published on ILM peel size showed a significant effect on closure, with no detrimental effect on visual acuity when the peel size extended to >1 disc diameter in radius (<2DD in all studies). The effect became clinically recognisable above 400 microns in MLD and reached a peak effect at approximately 500 microns suggesting that 400 microns would be an appropriate level to perform a larger diameter peel.

The ILM flap technique appears to improve the closure of large iFTMH. There is less agreement though on whether the presence of a non-neural ILM sheet in or above the macular hole affects the visual prognosis in any way. Michalewska et al also found that ILM flap leads to higher anatomical success as well as improved functional outcomes.²³⁸ Alternatively, there has been some suggestion by other authors that recovery of external limiting membrane and improvement in visual acuity may not be as good with ILM flap when compared to traditional ILM peel.²³⁹

There are 4 RCTs comparing ILM flaps with ILM peel. The original RCT was by Michalewska et al in 2010 described above.²¹⁸ In this single-centre (and single surgeon) trial including iFTMH of >400 µm, 50 patients randomised to ILM flap had a 98% anatomical success rate (flat-open macular hole was considered a success), whereas the standard ILM peel had an 88% success rate. When flat-open FTMH were excluded, the success rate of ILM peel dropped to 69%. This is significantly lower than the generally accepted standard of around 90%. Snellen charts were used for visual acuity testing and there was no information on how the sample size for the trial was estimated. A major reason for the low success rate of ILM peel may have been that only air tamponade was used following ILM peel which is not the current established practice worldwide. Velez-Montoya and associates randomized 12 patients with iFTMH of >400 µm in each of two groups, inverted ILM flap and conventional ILM peeling, and found no differences in the macular hole closure rate between groups ($p = 0.85$) at 3 months follow-up.²³² Both groups improved after surgery by at least 0.2 logMAR but only the inverted flap group reached statistical significance at the end of the follow-up period. The number of patients recruited in this study was too small to draw a meaningful conclusion. A prospective randomised trial by Manasa et al compared the outcomes in the standard ILM peel versus ILM flaps in 100 patients with idiopathic macular holes 600µm or larger.²³³ The standard peel group improved to a final mean BCVA of 0.86 ± 0.19 logMAR versus 0.67 ± 0.30 in the flap group postoperatively ($p = 0.001$). The difference in anatomical closure rate was statistically different between the 2 groups ($p=0.02$). They concluded that ILM flap provides superior outcomes compared to standard peel and, hence, could be considered as the surgical modality of choice in large iFTMH. However, follow-up was limited to 3 months, there was inadequate sample size, and no masking of outcome assessors leading to performance bias. Another prospective randomized control trial by Kannan and associates looked at patients with FTMH of diameters ranging from 600µm to 1500µm.²³⁴ The anatomical closure rate was 76.7% with standard ILM peeling and 90% with the ILM flap. There was a clear trend of a higher anatomical success rate and better functional outcomes with ILM flaps. Again, the study was not adequately powered with only 30 patients in each group, and the difference did not reach statistical significance. Additionally, there was no masking of personnel and outcome assessment leading to performance and detection bias. In two of the latter three RCTs Snellen visual acuity charts were used.

A Cochrane Review looked at these 4 RCTS comparing ILM flap with conventional ILM peel for large iFTMH (285 eyes of 275 patients).²³⁵ The authors found moderate certainty evidence that ILM flap increases overall and type 1 closures (presence of neurosensory retina in iFTMH), and low certainty evidence that ILM flap gives superior best-corrected visual acuity (BCVA) gains at 3 or more months after surgery when compared with conventional ILM peel. Another meta-analysis by Chen et al looked at these 4 RCTs and came to similar conclusions that ILM flap gave superior anatomic success, type 1 closures, postoperative logMAR BCVA and mean change of logMAR BCVA from baseline.²⁴⁰ A meta-analysis by Yu et al²⁴¹ analysed these 4 RCTs plus another RCT comparing ILM flaps to ILM peel combined with subretinal macular fluid aspiration as a part of the procedure.²⁴² Anatomical

closure rate of iFTMH and postoperative BCVA was better for ILM flaps, although it is possible the subretinal fluid aspiration could have affected the results. A sub-group meta-analysis showed that postoperative BCVA was better for the ILM flap group at 3 months when compared to ILM peel, but no significant difference was found at 6 months. A systematic review and meta-analysis by Shen et al included 4 RCTs and 4 retrospective studies and concluded that closure rate for iFTMH was statistically significantly higher for ILM flaps.²⁴³ The postoperative visual acuity was again better in the ILM flap group at 3 months, but no difference in visual outcomes was found at 6 months. Another meta-analysis by Marques et al showed higher anatomical closure rate but not superior BCVA outcomes for ILM flaps when compared to ILM peel.²⁴⁴

A recent retrospectively analysed consecutive case series using prospectively collected data of 191 patients with holes greater than 500 microns in MLD by two surgeons using a superior based single layer ILM flap technique showed a significantly improved closure rate with an adjusted OR of 5.8, (95% CI = 1.3 to 25.6, $p = 0.020$).

Summary

Peeling of the ILM is an integral part of macular hole surgery. With the use of adjuvant dyes and modern instrumentation it can be carried out safely and reliably in almost all patients undergoing macular hole surgery. Peeling of the ILM may have consequences for the underlying retina, especially as a part of the learning curve of this surgery. Traditional ILM peel as a part of vitrectomy leads to consistently high anatomical closure rates of 90 percent or higher for iFTMH < 500 microns in MLD. For larger and chronic iFTMH, the ILM flap technique with all its variations is a useful approach in the armamentarium of a vitreoretinal surgeon. Further studies are needed to look at the long-term functional outcomes of ILM flaps, and well as for a customised approach to ILM peel for iFTMH of various sizes and chronicity.

Research Need

Current evidence including small RCTs suggest that inverted ILM flaps are possibly more successful than standard ILM peeling in anatomically closing macular holes. However, there has been no adequately powered high-quality RCT to answer this question definitely, and more so answer the more crucial question of which ILM flap technique gives a better functional outcome in terms of improvement in visual acuity and distortion. A robustly designed trial looking at the anatomical and functional outcomes of the standard technique of PPV with ILM peel versus PPV with ILM flap could be performed to look in particular at patients with iFTMH larger than 500 microns, and increase the evidence base for the preferred technique in large macular holes.

Section 7c. Tamponade considerations

Background

Since its introduction intraocular tamponade has been a key part of iFTMH surgery.¹⁷⁸ Tamponade is believed to aid hole closure by three different mechanisms. The tamponade agent spans the hole to prevent trans-hole fluid flow from the vitreous cavity, allowing effective retinal pigment epithelium (RPE) mediated subretinal fluid removal and, probably, in addition, reduction of concomitant retinal oedema. The tamponade also creates interfacial surface tension forces between the edges of the macular hole and the gas bubble, which may act to pull the edges of the hole together, promoting hole closure. Finally, hypothetically the tamponade may act as a 'surface' to allow glial cell migration between the retinal edges.^{58,101,245}

The "buoyant force" of a gas bubble on a macular hole in the face-down position (FDP) is thought to be less important, particularly, if all tangential force has been removed with removal of the ILM and any co-existent ERM.⁽⁴⁾ Bridging of the gap by the tamponade is the principal mechanism of action but it is possible the buoyant force may be additive in certain circumstances.²⁴⁶

The choice of the optimum tamponade for macular hole surgery is an important clinical question. Its duration affects visual recovery and patients' activities. Several considerations are relevant in this regard, including the requirement for positioning, the period of reduced vision whilst the gas is present, the ability of the patient to go to high altitudes (e.g., air travel) and the potential risk of complications. These are modulated by hole specific factors such as size and chronicity i.e., large, and more chronic holes may require longer tamponade than small and more recent onset ones.^{93,247}

Although Kelly and Wendel used sulphur hexafluoride (SF₆) gas as a tamponade agent, when the procedure was subsequently adopted, most surgeons initially chose to use long-acting gas (C₃F₈) to maintain gas related hole bridging for as long as possible. Some surgeons have also used silicone oil for similar reasons. However, there has been a gradual change in practice to increasing use of medium (C₂F₆) and short-acting gases (SF₆) or even air. At the same time there has also been a recognition that FDP (see posturing section) may not be as important as initially thought in most macular holes.⁸⁶

It can be hypothesised that there is a relationship between tamponade choice and posturing requirement that relates to the amount of time the gas needs to bridge the hole. Gas can still bridge the defect of a macular hole without face-down positioning in an upright position if the gas fill of the vitreous cavity exceeds 50%, and long-acting tamponades will maintain this fill for a longer period than air or short-acting gases.²⁴⁷ The precise time the tamponade needs to bridge a macular hole to result in hole closure is, however, uncertain. Indeed, the known spontaneous closure of macular holes as well as that following enzymatically induced vitreo-macular separation shows that tamponade may not be necessary for all macular holes to close. Moreover, a recent RCT that included 80 eyes (mean MLD 317microns, 14 holes >400 microns treated with ILM flap) randomised to 3 days FDP versus no specific positioning instructions, using optical coherence tomography (OCT) for the first three days showed that approximately 90% of holes were closed by postoperative day 2, and none of the eyes with confirmed closure by postoperative day 3 had later reopening by 3 months.²⁴⁸ Therefore, a longer lasting tamponade may not be necessary for some patients based on certain parameters, such as macular hole size and symptom duration. Macular hole size is known to be an important factor for surgical failure and a key parameter to consider for tamponade selection. Hole chronicity is also significant with likely reduced retinal compliance resisting closure.⁹³

There are, thus, several factors that surgeons must consider when choosing an intraocular tamponade. Studies evaluating the effectiveness of differing tamponade agents in the treatment of iFTMH have used differing posturing regimes, included holes of differing size and chronicity, and some did not take into consideration important manoeuvres known to affect hole closure (e.g., ILM peeling), making interpretation of the evidence complex.

Question 7.9: Which is the most effective tamponade agent to use with vitrectomy for iFTMH?

GRADE: MODERATE, SIGN Grade: B

SF6, C2F6, C3F8 are all equally effective in achieving hole closure and distance visual acuity improvement when combined with vitrectomy and standard ILM peeling.^{249,250,251,252}

GRADE: MODERATE, SIGN Grade: B

Air is inferior to SF6 in achieving hole closure in those less than 400 microns when combined with vitrectomy and standard ILM peeling without FDP. It may be as effective as SF6 in small holes less than 250 microns.^{2,253}

GRADE: VERY LOW, SIGN Grade: C

There is no evidence that differing tamponade agents alter the effect of hole size and postoperative FDP in achieving closure.²⁵²

GRADE: VERY LOW, SIGN Grade: C

Silicone oil does not improve hole closure as compared to gas tamponade when combined with vitrectomy and standard ILM peeling. The effect on visual acuity is uncertain but the use of oil is known to be associated with a higher rate of complications, including unexplained visual loss, than gas.²⁵²

Summary of evidence and comment

Based on 3 RCTs and 1 systematic review and aggregate metanalysis which included 2 of the 3 RCTs published to date, we found no statistically nor clinically significant difference in closure rate or visual outcome between SF6 versus C2F6 or C3F8.

A recent Australian, registry-based, cohort study of approximately 2500 eyes also found that SF6 gas was non-inferior based on a 5% margin as compared to longer acting gases for holes of all sizes. Similarly, the UK BEAVRS group in a large database study of approximately 1500 eyes found no difference in closure nor visual acuity between the three gases in holes of any size. In both series the hole size was included in the regression analysis.

The aggregate metanalysis found no clear evidence for an interacting effect of postoperative FDP and hole size in the comparisons. However, the trials published to date have had a variable case mix with disparate trial designs in terms of postoperative positioning, making conclusions imprecise with low/very low levels of certainty for this question.

Air has several advantages over SF6 including its shorter duration, its non-expansible nature with therefore a lower risk of raised IOP, not being a greenhouse gas in contrast to all the fluorinated gases particularly SF6, and finally being free. There has been one adequately powered RCT of 144 eyes showing that air tamponade was inferior to SF6 tamponade for hole closure with MHs of ≤ 400 microns in diameter without FDP based on a 10% non-inferiority margin. 90% (63 of 70) of the eyes randomised to air closed versus 100% (74 of 74) randomised to SF6. Another RCT of 104 eyes with low power to assess effect, and of unclear design found similar effects with air without FDP, 89% closure but a 100% success rate with FDP for holes <400 microns compared to 100% in both groups with SF6. It is possible air could be non-inferior in small holes, with closure being 100% in both groups in the first mentioned RCT but the study did not have an adequate sample size to definitively assess this group.

Silicone oil has not been shown to have any significant benefit regarding hole closure compared to gas. The evidence is very uncertain with no RCTs, and we were unable to assess visual outcomes. There are several limitations of silicone oil use including the necessity of a second surgery for removal and the potential for adverse events and toxicity and therefore its use is likely to remain limited to specific situations.

Adverse events were generally left to investigators to report at their own will rather than evaluated based on a pre-existing list and checked at each time point, incompletely reported and conclusions are limited.

The inconsistency of the analysed data in terms of hole size and the variability in postoperative positioning make the strength of the evidence base uncertain in large holes and when face down positioning is not instructed.

Summary and practice points

Short and longer acting gases may be all suitable for macular hole surgery with vitrectomy and ILM peeling based on several patient specific factors (chronicity, size, posturing preferences and compliance, travel requirements etc.). A patient-centred perspective should be followed in these cases, as well as keeping in mind factors including the time to visual rehabilitation after surgery. Air tamponade should only be considered in small holes where it may be as effective as gas.

Recently, ILM flap techniques have been described and, consequently, adopted by many vitreoretinal surgeons. ILM flaps appear to improve closure and may reduce the need for longer gas tamponade or postoperative positioning in larger holes. (See Section 7b).

Research need

Robustly designed RCTs with agreed reporting parameters, definitions of anatomical and functional success, prospectively determined adverse event reporting and including patient preference could help improving the evidence base for an appropriate tamponade selection. Particularly relevant comparisons with 2-armed RCT designs could be performed between short- and long-term gases without prescribed postoperative FDP, with planned sub-analyses for the effects of hole size and duration. Similarly, air could be usefully compared with short acting gas for small- and medium-sized holes with shorter durations and perhaps combined with short-term postoperative positioning instructions.

Section 7d: Combined phacovitrectomy

Background

Cataracts are very common following vitrectomy, especially in the >60-year-old age group and when long-acting gases are used. Visually significant cataract occurs in most patients undergoing vitrectomy for iFTMH within a year of surgery.^{254,255} Cataract surgery following vitrectomy has been associated with a higher rate of posterior capsule rupture and other intra-operative difficulties, including those associated with the lens-iris diaphragm syndrome (also referred to as reverse pupil block).²⁵⁶

Combined phacovitrectomy has been widely adopted during macular hole surgery to avoid the need for subsequent cataract surgery, speeding full visual rehabilitation.²⁵⁷ Given discrepancies between demand and capacity in the UK NHS and other publicly funded health services, combined phaco-vitrectomy has the potential of being more cost-effective than sequential surgery (i.e., phacoemulsification and intraocular lens implantation before or after vitrectomy) and obviates patients having to wait for their cataract surgery to be performed.²⁵⁸ The utility, safety and benefit of phacovitrectomy with ILM peeling was clearly demonstrated in the FILMS study, a high quality RCT comparing ILM peeling to no ILM peeling for iFTMH that mandated phacovitrectomy in all phakic patients.^{193,195} However, potential adverse effects of the procedure, as compared to vitrectomy followed by phacoemulsification if indicated, have been proposed by some to include a longer surgical time, higher incidence of posterior synechiae formation, posterior capsule opacity, intraocular lens-related complications, and a variable myopic shift in refraction (Summarized in ²⁵⁹) There is also the potential for phacoemulsification and IOL implant related complications, for example corneal edema, which could make the primary aims of the vitrectomy surgery including ILM peeling more challenging to achieve. An alternative strategy is phacoemulsification and IOL implant performed as a separate procedure sequentially a few weeks prior to vitrectomy surgery. This, however, could delay to greater or lesser extent, depending on waiting times, the repair of the macular hole.

Question 7.10: Is combined phacovitrectomy more effective than sequential (either before or after) cataract surgery?

Anatomical & visual outcomes:

GRADE: MODERATE, SIGN Grade: B

There is no definitive evidence that macular hole closure or reopening is affected by the sequence of surgery. Visual recovery can be delayed by cataract formation following vitrectomy, which can affect quality of life.^{259,260,261,262,263,264,265,266,267}

Complications:

GRADE: LOW, SIGN Grade: C

Posterior capsular tears may occur significantly less frequently with combined surgery than cataract surgery following vitrectomy (Risk ratio 0.43; 95% CI, 0.25-0.73). The incidence of other complications are not significantly different.^{259,260,261,262,263,264,265,266,267,268}

Refractive outcomes:

GRADE: MODERATE, SIGN Grade: B,

Refractive outcomes are not significantly different with either sequence of surgery.^{267,269,270}

Overall recommendation

Combined phacovitrectomy probably offers advantages over sequential surgery in terms of earlier recovery of vision, but at 12 months and after cataract surgery, if required there are no significant differences.

Evidence summary:

We found 3 systematic reviews, 2 RCTs, 2 prospective series and several retrospective case series.

Practice points

Cataract surgery is near inevitable on long term follow up after macular hole surgery with gas. Combined phacovitrectomy can be carried out without an increased risk of complications or worsened refractive outcomes as compared to cataract surgery following vitrectomy. Cataract development and subsequent surgery following vitrectomy however risks delaying visual recovery.

Section 7e: Postoperative posturing

Introduction

Face down positioning (FDP) after macular hole surgery continues to be routinely advised to patients by many vitreoretinal surgeons.²⁷¹

The rationale to support FDP is based on several factors that rely on the benefit of the extended duration of tamponade provided by the gas bubble. FDP is thought to isolate the FTMH from intraocular fluid and hence permit absorption of subfoveal fluid and re-apposition of the macular hole edges.⁵⁸ In addition, buoyancy force from the gas bubble may keep the macular hole against the retinal pigment epithelium.^{245,246} Surface tension from the gas bubble may help displace the fluid under the edge of the hole.²⁷² Both surface tension and buoyancy force effect is maximized with FDP as that ensures the centre of the hole is at the highest point of contact with the tamponade. In addition, the gas bubble may provide a scaffold for reparative glial cells to cover and close the hole.^{59,273}

However, there are also several arguments against FDP. FDP can be physically challenging for patients. The majority of patients describe FDP as difficult or very difficult.²⁷⁴ Rare but serious complications such as pulmonary embolism, ulnar nerve palsies and thrombophlebitis have been reported with FDP.²⁷⁵ Patient compliance with positioning is also often not achieved in clinical practice.²⁷⁶ In addition, evidence suggests that isolating the macular hole from intraocular fluid in the first 24 hours is likely the most important factor in terms of achieving hole closure and a large gas bubble could achieve effective tamponade and isolate the FTMH even without FDP.⁶

To date, there have been 8 RCTs that have tested FDP versus no FDP post-operatively for macular hole repair. There have also been systematic reviews and meta-analysis assessing the body evidence on the topic with the most recent meta-analysis published in 2023.

Question 7.11: Is face down posturing (FDP) more effective than no face down posturing (nFDP)?

1. For macular holes less than 400 microns in MLD, FDP achieves similar closure rate and similar vision gains compared to non-FDP. **GRADE: MODERATE, SIGN Grade A** ^{230,253,275,277,278,279,280,281}
2. Ye T, Yu JG, Liao L, Liu L, Xia T, Yang LL. Macular hole surgery recovery with and without face-downposturing: a meta-analysis of randomized controlled trials. *BMC Ophthalmol.* 2019 Dec 21;19(1):265. **SIGN Grade 1+**
3. For macular holes 400 microns or greater in MLD, FDP may achieve higher closure rate. **GRADE: LOW, SIGN Grade B** ^{230,278,279,281,282,283,284}
4. FDP may result in a slight benefit in terms of visual acuity **GRADE: LOW, SIGN Grade A**²⁸⁵

5. In cases where no FDP is recommended, ILM peel should be carried out, a large gas fill with long-acting gas tamponade (not air) used and patients asked to avoid supine position for 10 days. **GRADE: MODERATE, SIGN Grade A** ^{247,253,275,277,279,286}
6. In cases where FDP is recommended, 3 days 80% of the time or 5 days for at least 8 hours daily and avoiding supine positioning at all times should be suggested. **GRADE: LOW, SIGN Grade B** ^{230,287}
7. FDP or no FDP closure rates are not impacted by the type of gas used, however air should be avoided in no FDP cases **GRADE: LOW, SIGN Grade B** ²⁸⁰
8. Patients with sub-optimal gas fill (90% fill on day 1 or around 80% at day 4) should be considered for FDP **GRADE: LOW, SIGN Grade C** ^{247,248,275,277}
9. No FDP position provides enhanced patient comfort and quality of life compared to FDP. **GRADE: LOW, SIGN Grade C** ^{253,280,282}

Summary of how you reached levels of evidence

In total, eight RCTs and 5 systematic reviews and meta-analysis were used to establish the level of evidence. ^{230,247,248,253,275,277,278,279,280,282,283,284,286}

Risk of bias (ROB) for each RCT was low for the outcome of macular hole closure rates for all RCTs except Guillaubey²⁸⁷ where it was unclear how random sequence generation was carried out. The ROB for each RCT was moderate for VA outcomes as patients could not be masked to intervention (FDP versus nFDP).

In terms of the meta-analysis, all 5 meta-analyses ^{230,280,283,284,286} had clear, well-defined question and detailed description of methods used to identify and evaluate studies was described. A systematic and reproducible literature search strategy was presented. Study quality was taken into account. The studies included in each meta-analysis had similar patient populations and similar methods to assess outcomes including hole closure and visual acuity assessment.

There is high quality RCT evidence and meta-analysis evidence to suggest that no FDP is non-inferior to FDP in terms of hole closure rate for iFTMH < 400 microns.

In terms of iFTMH 400 microns or greater in MLD, there remains conflicting evidence in terms of impact of FDP versus no FDP on hole closure rate. Historically, evidence synthesis appears to suggest a positive effect of FDP on hole closure rate for this sub-group. Meta-analysis by Hu et al²⁸⁴ included four RCTs and demonstrated in sub-group analysis an increase odds of hole closure with FDP versus no FDP for holes over 400 microns (OR = 0.23, 95% CI [0.07, 0.71, p=0.01). Ye et al²³⁰ carried in their meta-analysis also demonstrated in sub-group analysis an increase odds of hole closure with FDP versus n FDP (OR=2.95, 95% CI:1.10,7.94, P=0.03). Tsai et al²⁸³ also demonstrated a positive treatment effect for FDP on closure rate (OR = 3.34 (1.57,7.14).

However, the largest and most recent meta-analysis by Chaudhary et al²⁸⁰ did not demonstrate a difference between FDP versus no FDP with respect to iFTMH closure for iFTMH of all sizes, although the confidence intervals were wide (RR 1.05 (95% CI: 0.99, 1.12, P=0.09, Grade rating LOW). In terms of absolute effect (95% CI) on hole closure rate for FDP vs no FDP, this translated to 43 more per 1,000 cases (from 9 fewer to 104 more). A prespecified analysis to determine subgroup interaction based on hole size (<400 microns and >400 microns) was reported and did not demonstrate a benefit for FDP for holes > 400 microns (no effect, ICEMAN tool: LOW credibility). Of note, Chaudhary et al report Risk Ratio versus Odds Ratio reported in previous meta-analysis. ORs and risk ratios diverge when event rates are high, as it the case for hole closure after surgery. Moreover, the lower CIs in previous meta-analysis described above suggest a small benefit with FDP which is similar conclusion that can be drawn from Chaudhary et al's meta-analysis based on the upper CI of their findings.

Ultimately, the totality of evidence synthesis to date on effect size of FDP on hole closure rate for iFTMH 400 microns or greater in MLD demonstrates lack of precision which lowers the confidence in any recommendation on positioning for this sub-group of patients. Therefore, it is important that patient values and preferences are incorporated into decision making as it pertains to recommendation of FDP or no FDP for iFTMH 400 microns or greater in MLD.

Practice points

FDP does not improve closure for iFTMH < 400 microns.

FDP can be recommended for iFTMH 400-microns or greater, however, patients should be informed about the uncertainty around a definitive positive impact of strict FDP on hole closure rate and patient values and preferences should guide decision making.

FDP may result in a slight benefit in terms of visual acuity.

For recommendation for no FDP, there are some important caveats that should be considered. The surgical technique in majority of RCTs involved ILM peeling and gas tamponade (not air). Studies demonstrate that a large gas fill is likely an important factor for success and if day 1 the gas fill is noted to be suboptimal, consideration should be given to encouraging FDP. Pseudophakia may allow for larger gas fill compared to phakic eyes. Patients who follow no FDP should avoid supine positioning at any time for the first 7 days post-operatively.

Research need

1. Lack of precision in effect size for FDP versus no FDP on hole closure rate in iFTMH 400 microns or greater suggests need for further robust RCTs on the topic.
2. Dichotomous classification of iFTMH in small (<400 microns) and large (400 microns or greater) is an arbitrary classification. Future studies including IPD meta-analysis should be carried out to assess other thresholds such as 500 microns or 600 microns to assess the impact of positioning on hole closure rate.
3. There is paucity of RCT data on key patient reported outcome measures and patient experience on the role of positioning in macular hole surgery and future studies should incorporate validated measures to assess such outcomes.
4. Impact of positioning on hole closure rates after ILM flaps should be assessed in future RCT.

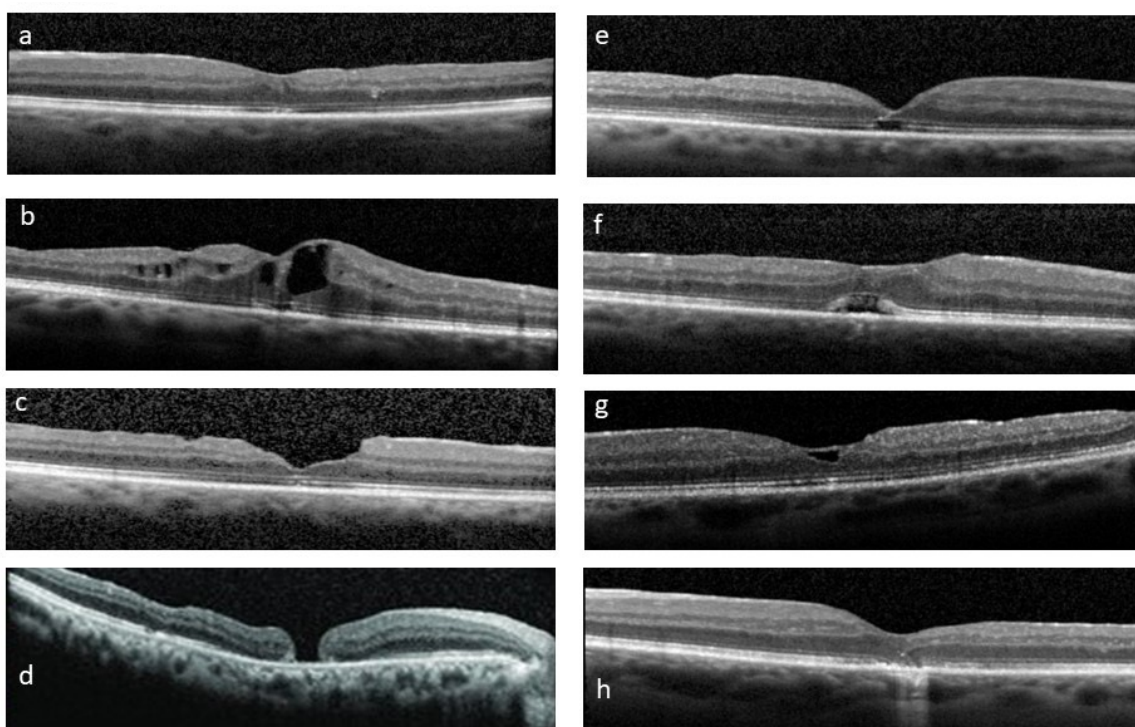
8. Outcomes

Outcomes of macular hole surgery can be divided into anatomical and functional. Functional outcomes include visual acuity, metamorphopsia, and patient related outcome measures, such as the VFQ-25.

Anatomical outcome

Anatomical outcomes have historically been binary – either open or closed. However, with higher quality imaging, it is possible to detect different closure patterns (See figure 8) Twenty years ago, closure was divided into Type 1, in which there was full restoration of the retinal layers, and Type 2, in which the hole appeared closed but there remained exposed RPE.²⁸⁹ Eyes that had Type 2 closure had worse visual acuity, and less visual improvement. With improved resolution, OCT classifications of closure have become more detailed. In addition, newer surgical techniques, such as retinal autografts, or amniotic membrane insertion, have raised questions regarding whether “closure” is restoring retinal anatomy, or merely plugging the hole. The most detailed classification of closure recognises three types of closure, each of which are further sub-divided into three subtypes.²⁹⁰ Type 0 corresponds to an open hole, the edges of which may be flat (0A), elevated (0B), or oedematous (0C). Type 1 closure includes all holes closed with some restoration of normal foveal microstructure. In Type 1A, all layers of the fovea are restored. In Type 1B, the inner layers are restored, but there is a persistent outer retinal defect. In 1C closure, the outer retinal layers are present, but the inner layers are not restored. Type 1 closure is observed after macular hole surgery with ILM peeling or inverted ILM flap. Type 2 closure is observed most frequently following amniotic membrane or retinal autograft techniques. In Type 2 closure there is an interruption to the normal foveal layers, although there is no exposed RPE. In Type 2A, the interruption extends through the entire foveal thickness, 2B affects only the outer retina, and 2C the inner retina. Type 1 closure was associated with the best post-operative visual acuity, and Type 2 closure had better vision than Type 0. In practice most reports of anatomical outcomes are limited to open or closed.

Figure 8: Postoperative appearances. A (type 1a closure), b (type 1b closure with cystoid macular oedema), c (type 1c closure with DONFL appearance), d (type 2 closure or now known as type OA), e (type 1b closure), f (type 1b closure with subfoveal cysts), g (type 1a closure with ILM flap visible), h (type 2b closure).



Anatomical hole closure is achieved with one operation in over 90% of macular hole surgeries in large (>1,000 eyes) real world database studies.^{86,291} The probability of successful closure is influenced by the size of the hole, its duration, the surgical technique employed, and post-operative management. The latter two issues will be addressed elsewhere in these guidelines.

Hole size

Historically macular holes with a minimum linear diameter greater than 400µm have been regarded as large.²⁹² More recently, the International Vitreomacular Traction Study Group proposed further subdivision of holes into small (<250µm), medium (250µm – 400µm), and large (>400µm).⁸¹ Holes less than 250µm are more likely to close with enzymatic vitreolysis compared to larger holes. However, with current macular hole surgery techniques, there is little difference in the success rates for holes less than 450 microns with closure rates of >90%.⁸⁶ The success rates only declines when the hole diameter is greater than approximately 500 microns.^{86,293} The CLOSE study examined anatomical outcomes in 1135 eyes >400µm in 31 published articles.¹¹³ They found that in large holes (400-535 microns), the closure rate was 97%. In X-large holes (536-799), the single operation success rate declines to 90%. Holes between 800 and 1,000µm were classified as XX-large, and those above 1,000 microns were labelled as Giant. The authors showed that success rates with standard ILM peeling were excellent until the hole diameter exceeded 535 microns. For X-large holes, ILM flaps have good results. Holes over 800µm are uncommon but may require other adjuvant techniques to achieve higher rates of closure, although the evidence base is very low on these sized holes currently.

As the size of the hole is important in determining the prognosis and dictating the surgical technique, accurate and reliable measurement is crucial. Unfortunately, measurement of macular hole diameter is usually done manually, and there is significant interobserver variation.⁸³ Accuracy may be improved using multiple radial scans, or high-density horizontal scans. Automated measurement of macular hole dimensions would be less subject to interobserver variation and may be more reliable.²⁹⁴ Furthermore, holes enlarge over time, so a hole that is 460 microns at presentation may be 540 microns by the time of surgery.^{295,296} Given these uncertainties, surgical decision-making should ideally be based on more than one measurement, and at least one of these measurements should be no more than four weeks prior to surgery.

Other measures of macular holes have been proposed. These include the macular hole index, which is the ratio of the hole diameter to the height, macular hole form factor, and other indices. However, there is little evidence that any of these calculated measurements are more accurate predictors of outcome than macular hole diameter.²⁹⁷ Furthermore, these indices are closely correlated with standard measurements of hole size.

Vitreoretinal adhesion

There is no evidence that differences in vitreoretinal adhesion to the hole have any effect on anatomical outcomes.⁸⁶

Ethnicity

Black or South Asian ethnicity has been linked to reduced rates of anatomical closure,²⁹⁸ however it is also linked to larger hole size, and possibly to greater duration,^{18,298} and not all studies have shown that ethnicity is an independent risk factor for failure.

Duration

As duration is linked to size, it is difficult to be sure if duration is an independent predictor of anatomical closure, but an individual participant study of data extracted from 12 RCTs has shown that every additional month of duration is associated with a reduced probability of closure, independent of the hole diameter.⁹³ **SIGN Grade 1++**

Question 8.1: Does symptom duration affect anatomical outcome in iFTMH?

Increasing symptom duration reduces the chance of closure. The effects are most marked in small recent onset holes.⁹³

GRADE: MODERATE, SIGN Grade: B

Visual acuity outcomes

Anatomical outcomes for macular hole surgery are predictable and are dependent on hole size and surgical technique. In holes up to 800µm, with appropriate surgery (e.g. with ILM flaps in holes over 500 microns), closure rates can exceed 90%. Visual acuity outcomes are more variable and are influenced by factors other than hole size and surgery. A large UK study found that 46% of eyes achieved a post-operative vision equivalent to 70 letters or better.⁸⁶ This shows an improvement from studies conducted a decade earlier, in which 33% regained 70 letters or better.²⁹⁹ Some series have shown 60% of eye regaining 70 letters. Postoperative visual acuity is associated strongly with preoperative visual acuity which was 0.78 in Steel et al⁸⁶ and ~0.65 in the study by Lachance et al.³⁰⁰ Visual acuity also improves with longer follow-up,^{291,300} so studies that follow patients for longer tend to have better visual acuity results.

Although visual outcomes vary, there is broad agreement on the factors that affect final vision. Better pre-operative vision is strongly associated with better post-op vision.^{86, 297, 299, 300, 301} Smaller hole diameter is associated with better final visual acuity, 86 113 however, smaller holes are also associated with better pre-operative vision, and some studies have not found that hole size is an independent predictor of final vision.³⁰⁰ Apart from hole diameter, an elevated edge of the hole is another OCT parameter that may be associated with better final vision.³⁰⁰

Holes with a shorter duration will have better vision.^{86, 300, 301} A recent study that examined duration as a risk factor found that the final vision decreased by 1 ETDRS letter for every two months duration.⁹³ Increasing age is associated with worse visual outcomes in some studies,²⁹⁹ but in others, age was not a risk factor for poor vision, but age-related-macular degeneration was.⁸⁶ As there is a close relationship between increasing age and the prevalence of age-related macular degeneration, it seems likely that association of age with worse visual outcome is due to the increased risk of pre-existing macular disease. In the absence of age-related macular degeneration, older age should not be regarded as a negative prognostic indicator. There is broad agreement that pseudophakia at follow-up is associated with better final visual acuity.³⁰⁰

Question 8.2: Does symptom duration affect visual outcome with surgery in iFTMH?

Increasing symptom duration reduces the postoperative visual acuity. The effects are most marked in small recent onset holes.⁹³

Sign Grade: B GRADE: Moderate

Practice point

Increasing symptom duration reduces both anatomical and visual outcomes and waiting time to surgery will affect the results of surgery. People presenting with iFTMH would optimally have surgery at timing commensurate with their symptom duration (i.e., a person with a 2-month history of a macular hole should have surgery within 2 months, those with a 3-month history should have surgery within 3 months, etc. Surgery should not be delayed in any case more than 3-4 months.

The time between onset of symptoms and surgery can be divided into three components (Raimondi et al.):

1. Onset of symptoms to first consultation with eye care provider.
2. Initial contact with eye care provider to listing for surgery.
3. Listing for surgery to the day of operation.

It is difficult to reduce the time from onset to initial consultation in everyone, as some patients are asymptomatic. As part of normal public health messaging, people should be encouraged to consult an appropriate eye health care provider as soon as possible if they experience any deterioration in their vision. Reducing the delay from deciding to have surgery to the day of the operation requires investment in additional operating time, so may be costly. Reducing the delay from initial consultation to listing for surgery is relatively achievable, and inexpensive, in comparison to other measures. For example, patients with suspected iFTMH can be seen in a fast-track OCT clinic and listed directly for surgery via telephone consultation⁸⁶

Patient-related outcome measures

Although most patients with FTMH will have good vision in the fellow eye, the presence of an iFTMH nonetheless has an impact on their vision related quality of life. Using the VFQ-25, studies have shown a consistent pre-operative composite score of around 70, improving to 80 after surgery.^{302, 303, 304, 305, 306} In the FILMS trial VFQ-25 scores were higher, at 80 before surgery, and 86 post-operatively.³⁰⁷ There is relatively little data on which pre-operative factors predict QoL outcome. There is good correlation between pre-operative and post-operative QoL scores.³⁰⁵ Patients with worse QoL scores pre-operatively tended to have greater improvement. Although some studies have shown improved visual acuity predicts improved QoL score,³⁰³ most have found no relationship between improved VA and increased QoL score.^{304, 305, 306} Where metamorphopsia is measured, an improvement in the M-chart metamorphopsia score seems to be a better predictor of an increased VFQ-25 composite score.^{304, 306}

Metamorphopsia

Metamorphopsia is easy to detect, but more difficult to quantify. M-charts have been used in most series; however, the lines are made up of small dots, and a visual acuity of 6/24 or better is required for accurate assessment. Arimura³⁰⁸ found that metamorphopsia, as measured with M-charts improved in 19 out of 22 patients who had macular hole surgery. Other researchers have confirmed that metamorphopsia improves after successful hole closure, and this improvement is not always related to improvement in visual acuity).² An alternative to M-charts that can be used in eyes with vision of 6/60 or better is D-charts. D-charts also show an improvement in metamorphopsia following macular hole surgery.³⁰⁹

9. Follow-up and further management

Background

There is wide variation in practice with timing of post operative review of iFTMH patients across the United Kingdom.¹²⁷ Traditionally, a day 1 postoperative check has been performed and several studies have been performed to assess the necessity for this, based on earlier studies suggesting a high risk of problems.³¹⁰ Macular hole surgery is now typically carried out as day case surgery, making day 1 review less convenient. The rate of local anaesthesia has also increased from 33% in 2001, to 66% in 2010, and 88% in 2019, making general anaesthesia-related problems less common.^{127, 311, 312}

Raised intraocular pressure is the most common post operative complication of concern,^{127, 313, 314, 315, 316} however studies have tended to produce conflicting results,³¹⁶ with a reducing trend for postoperative adverse events with transconjunctival sutureless surgery.^{173, 317} The use of prophylactic intraocular pressure (IOP)-lowering treatments has also varied between studies. Day 1 review has an associated economic cost and is also inconvenient for patients, who may be required to travel long distances to access a specialist vitreoretinal service.

As a result of this many units have stopped day 1 review. In a BEAVRS survey of 250 surgeons in 2023 with a 35 % response rate, 63% of units now no longer carry out day 1 review. Of the units that no longer carry out day 1 review, 34% review within the first 1 week and 50% within the first two weeks. (Hakim et al, BEAVRS Meeting 2023)

The number of postoperative review visits outside the immediate postop period is also variable. Re-opening of holes after 3 months post operatively is uncommon (See chapter 11). Related to the progressive recovery of photoreceptor function, visual acuity is usually better with longer follow up.^{207, 318, 319} An initial review at 2-4 weeks postoperatively, when the fovea is visible, aims to detect closure, and complications such as retinal detachment, IOL problems or raised intraocular pressure. A further review at 3-6 month is then typically carried out, depending on the type of gas tamponade used, for visual acuity assessment and the detection of other longer-term problems such as cataract if relevant and cystoid macular oedema (see chapter 10).

Question 9.1: Should the patient be reviewed on Day 1

The absolute requirement for a day 1 review is uncertain. The incidence of events that require intervention on day 1 vary with a mean of 4.7% (95% CI 3.0-13.9), with raised IOP being the most frequent. Prophylactic IOP-lowering agents (topical 1% apraclonidine or CAI/Beta blocker combinations at time of surgery) should be considered to reduce this occurrence when Day 1 review is omitted, particularly for cases with glaucoma or previously raised intraocular pressure.

GRADE: LOW, SIGN Grade: C

Questions 9.2: What is the longest acceptable initial follow up

The optimal timing of this is not certain but typically patients are seen within the first 4 weeks, when the gas bubble has absorbed enough to assess hole closure. It will also depend on whether day 1 review has been carried out (if not typically seen sooner) and the risk of other complications (e.g., pre-existing glaucoma).

GRADE: VERY LOW, SIGN Grade: D

Question 9.3: How often and when should the patient be reviewed after the first postoperative visit?

There is very low certainty evidence to assess the precise requirement for timing or frequency of review after the initial postoperative review appointment. Patients should be seen after all gas has absorbed. The type of gas tamponade used, and management of any complications affect the decision. Thus, it is down to the clinician managing the patient and patient preference. Visual acuity improves for at least 6 months and can continue to improve for several years.

GRADE: VERY LOW, SIGN Grade: D

Question 9.4: What should be included in a post-operative review?

There is very low certainty evidence but widespread agreement on what should be included in post-operative review. As a minimum, post-operative review should include:

- Discussion between patient and clinician of any issues since surgery, discuss patient queries and check drop and posturing compliance.
- Visual acuity assessment (ideally with refraction following gas bubble absorption and typically 2 months or more following surgery)
- Intraocular pressure check
- Slit lamp examination of anterior and posterior segments including measurement of the level of gas bubble remaining.
- If the gas absorption allows a view of the macula, OCT scan to determine the status of the previously present iFTMH.
- Medication review to manage any new issues such as intraocular pressure spikes or inflammation.

GRADE: VERY LOW, SIGN Grade: D

Summary of evidence and comment

We found one systematic review³¹⁶ of 2,262 patients from 14 non-randomised retro- and prospective studies, which included 78 eyes with iFTMH, with a total day 1 intervention rate of 4.7% (95% CI 3.0-13.9), the majority of which were raised IOP. High heterogeneity by indication for surgery was found, and subgroups analyses could not be made because of data inadequacy.

Alexander et al,³¹³ in a retrospective analysis of 273 patients with a range of VR surgical indications (33 with iFTMH), found that 3.7% had clinical findings significant enough to require a change in management, but only 0.7% (2/273) had raised IOP (>30mmHg) on day 1. All patients received prophylactic treatment with oral acetazolamide and a topical beta blocker.

Hakim et al, in a prospective UK study of 430 eyes undergoing a range of VR surgical procedures, included 62 with macular hole (BEAVRS meeting, Birmingham 2023). Of the 430, 22(5%) had day 1 problems, of which 10 (45%) were raised IOP over 30mmHg. Of the 10 patients with high IOP, 50% had pre-existing glaucoma or ocular hypertension and 80% had gas used (exceptions were 1 oil and 1 air cases). No IOP prophylaxis was given. In the iFTMH group, 6% (4/62) had raised IOP.

Brennan et al,³²⁰ in a retrospective study of 176 eyes after a range of VR surgical indications all with day 1 review performed, found that 22% (4/18) of the patients with iFTMH had a day 1 IOP >30mmHg. No IOP prophylaxis was given.

Ringeisen et al,³¹⁵ in a retrospective study of 428 (39 with iFTMH) patients examined on day 1, found that 17(4%) had a IOP >30mmHg. No IOP prophylaxis was given.

Wong et al,³¹⁴ in a prospective study of 235 patients (22 with iFTMH) examined on day 1, found a 20% occurrence of raised IOP>30mmHg when gas was used. No IOP prophylaxis was given.

We found two RCTs showing that postoperative IOP spikes can be reduced by prophylaxis. Benz et al,³²¹ in an RCT of 50 eyes (5 with iFTMH), showed a statistically significant reduction in postoperative IOP comparing a combination drop of timolol 0.5%/dorzolamide 2% to placebo, given at the completion of surgery. Sciscio and Caswell,³²² in an RCT of 26 eyes of patients undergoing surgery for iFTMH, administered topical apraclonidine 1% 2 hours prior to and at completion of surgery, and found a significant reduction in day 1 postoperative IOP relative to placebo.

Practice points

Day 1 review varies according to surgeon practice, patient particulars, and the capacity to see patients on day 1. Some surgeons use it as an additional opportunity to stress aspects of postoperative care. It should be noted that if day 1 review is being omitted, careful consideration should also be made regarding gas concentration procedures, avoidance of expansile gas mixes and consideration of IOP reduction prophylaxis.

Furthermore, there should be written patient information leaflets advising the patient what to expect, drops, posturing advice and symptoms which should trigger urgent attention with emergency contact numbers for surgical unit.

Patient discharge should be considered when hole closure has been achieved, tamponade absorbed or removed, or when hole closure has not been achieved and no further treatment is desired. Typically, patients are reviewed at approximately 1-3 weeks postoperatively then again at 3-6 months before discharge. If the patient is phakic following surgery, lens assessment should be carried out and cataract surgery scheduled if indicated before discharge.

10. Complications

Complications of macular hole surgery can be divided into 1) intra-operative, 2) early post-operative, 3) late post-operative. We are not reviewing complications related to local or general anaesthesia in this guideline.

1. Intra-operative

- a. Retinal breaks (<20%)** may occur at the posterior pole or retinal periphery during the induction of posterior vitreous separation, or in the retinal periphery during vitreous shaving. The incidence of retinal tears appears lower with small gauge sclerostomy vitrectomy techniques.^{200, 323, 324, 325, 326} Intraoperative detection and treatment usually avoids subsequent retinal detachment. (See Section 7a)
- b. Retinal/RPE/choroidal damage (variable, vision effecting <5%)** secondary to instrument trauma during ILM peeling. (See Section 7b)
- c. Suprachoroidal haemorrhage (Between 1:1000 to 10,000)** is a risk with any intraocular procedure and is not believed to be of any increased incidence in macular hole surgery.
- d. Lens damage variable, <10%** may occur due to inadvertent touch of the lens capsule by the vitrectomy instruments. Usually this occurs in the 10 o'clock or 2 o'clock meridians in line with the sclerostomies. The lens opacity may be localised or progress to form a general or posterior subcapsular cataract. Their presence may increase the risk of PCR with subsequent cataract surgery.

2. Early post-operative

- a. Elevated intraocular pressure (10-20%)** may occur as early as the first post-operative day and may be due to variable expansion of the gas tamponade agent, or gas dilution errors, as well as by trabecular meshwork obstruction from inflammatory/cellular debris. It is commoner in eyes with preexisting raised intraocular pressure and glaucoma, and in eyes with complications including lens surgery related complications. Steroid-related ocular hypertension can occur due to the topical steroid given post-operatively and usually occurs by 7-14 days post-operatively.³²⁷ Late IOP elevation has been reported in ~4% at 4 years. (See Section 9)
- b.** A transient posterior, star-shaped, feathery **cataract** is very common post-operatively in phakic eyes, induced by the desiccation effect of the gas tamponade on the posterior lens and usually clears within 2-3 weeks.
- c. Retinal detachment (<5%)** may occur due to a new peripheral retinal break forming possibly due to movement of the gas bubble against the residual vitreous base, or because of a missed retinal break or one identified but inadequately treated with retinopexy during the vitrectomy procedure. Retinal detachments can be detected inferiorly before complete resolution of the tamponade bubble has occurred.^{127, 287, 329}
- d. Visual field defects (<5%)** were one of the first complications of macular hole surgery to be reported. Various hypotheses have been proposed including traction on the nerve-fibre layer during induction of vitreous separation at the optic disc edge, elevated intraocular pressure during the procedure, air stream pressure on the optic disc during fluid-air exchange, or desiccation of the nerve-fibre layer in the presence of air/gas tamponade.³³⁰ The incidence was initially high in early reports in the 1990s but has declined in more recent studies.³³¹
- e. Subfoveal cysts or outer foveal defects (>50%).** Whilst not a complication *per se* these can be seen on OCT in the early post-operative period following reabsorption of gas and are probably due to the edges of the hole closing without completion of the reabsorption of the subfoveal fluid, and outer retinal restoration.^{53, 332, 333, 334} The reported prognosis for resolution within 12 months is high and they are not associated with a worsened prognosis.

- f. Cystoid macular oedema (<10%)** Thought to be typical Irvine-Gass related. Not shown to be higher after combined phacovitrectomy however.²⁶⁰ Typically, treated with topical NSAID and steroids, or less commonly intravitreal steroids.
- g. Retinal changes related to ILM peeling:** A variety of inner retinal changes have been described following ILM peeling, typically without symptoms or consequences. (See Section 7b) Eccentric macular hole(s), often again not causing symptoms and stable for long periods of time, have also been reported, occurring in 0.25% - 2.5% of cases. They are possibly related to retinal damage during ILM peeling and/or contraction of residual ILM or secondary premacular proliferation stimulated by ILM peeling.^{335,336}
- h. Paradoxical dye-related macular changes (<1%)** linked to the dyes used in ILM peeling has been reported. They have been more frequently observed when using ICG at high concentrations and during longer and higher light level exposures (See Section 7b)
- i. Endophthalmitis (Between 1:1000 to 10,000)** Common to all intraocular procedures and not thought to be higher in surgery for iFTMH as compared to other vitreoretinal procedures (See Section 7a).

3. Late post-operative

- a. Cataract (>80%).** Related to age, long-acting gas use and the oxidant effect of vitrectomy on the posterior lens. Combined phacoemulsification and vitrectomy surgery for macular hole is advocated by many surgeons. (See Section 7d).
- b. Reopening of macular hole (<5%)** following successful surgery (See Section 11b).
- c. Sympathetic ophthalmitis (~1-3/10,000)** Very rare but reported after single vitrectomy procedures including narrow gauge transconjunctival surgery. Commoner with multiple surgeries. Usually treatable with good outcome if diagnosed early and treated with steroids and immunosuppressants.^{337, 338, 339}

11a: Revision surgery for persistent iFTMH after unsuccessful surgery

Background

Most iFTMH anatomically close in the early postoperative course, typically within the first 3 days.²⁴⁸,³⁴⁰ Late closure after gaseous tamponade resorption has been described but is rare.³⁴¹ Similarly, once closed, later reopening is uncommon if ILM peeling has been performed (~0.5-1% after ILM peeling versus 5-10% after closure without ILM peeling).¹⁹⁴ (See Section 11c) Visual acuity improvement following successful closure is more gradual, with most improvement occurring in first 6 months but longer-term improvement occurring in some eyes up to 2-5 years particularly in larger and persistent holes with ancillary procedures. (See Section 8)³⁴²

For holes that don't close after initial surgery (persistent holes) several treatment options have been suggested including reinjection of tamponade and face down positioning; increasing the area of ILM removed; autologous platelet concentrate; lens capsular flap transplantation; autologous free ILM flap transplantation; macular hole hydro-dissection and retinal expansion, autologous retinal graft, silicone oil, human amniotic membrane, perifoveal relaxing retinotomy, and arcuate temporal retinotomy. Most of previously mentioned procedures carry greater interventional risk than simple re-gas or ILM peel extension. Silicone oil requires a third surgery to remove. Most ancillary procedures to promote closure in persistent holes should be considered "experimental".^{343,344,345,346,347,348,349}

Success rates for revision surgery in these persistent holes have varied depending on the initial clinical features of the primary hole (size, visual acuity, duration) and the type of primary surgery performed but are typically in the order of 70-90%. Closure in a persistent hole usually results in improved vision.^{350,351}

Question 11.1: Should surgery be considered for persistent iFTMH?

Re-do surgery should be considered dependant on patient wishes, clinical features and initial surgery.

GRADE: MODERATE, Sign Grade: B^{350,351}

Most persistent holes enlarge slightly after failed primary surgery, with a small drop in visual acuity over 24 months follow up. The overall probability of persistent iFTMH closure with revision surgery is 78% (95% confidence interval 71-84%). A 10 letter (2 line) gain in vision can be expected in 58% (95% confidence interval 45-71%) of patients undergoing surgery for persistent iFTMH. 15% regain a VA of 6/12 Snellen (0.3logMAR). Vision can continue to improve for 24 months after surgery.

Question 11.2: At what stage should re-treatment be offered for persistent holes after initial surgery?

Reoperation should be considered once all tamponade has been resorbed and/or 4 weeks have elapsed since surgery as a balance between earlier intervention and the small possibility that delayed closure will occur.

GRADE: LOW, SIGN Grade: C³⁴¹

Question 11.3: What treatment should be offered for holes that don't close with initial surgery?

GRADE: LOW, SIGN Grade B^{343,344,345,346,348,349}

Assuming an ILM peel has been performed, simple procedures with either insertion of gas or enlarging the ILM peel result in closure in 50-90% of persistent holes. Positive prognostic indicators for these relatively simple procedures alone being successful include holes that reduce in size after initial surgery, an increasing Macular Hole Index (MHI: height of hole divided by base diameter), the presence of an elevated fluid cuff around the hole and repeat surgery within 3 months of primary surgery.

There is very low certainty evidence that any other type of procedure is better than insertion of gas or enlargement of the peeled area. Comparison between techniques is very incomplete and clear recommendations cannot be made.^{348,349,353} (References I-M)

There have been 2 small RCTs comparing air versus SF6 tamponade in the use of amniotic membrane³⁵⁴ and Densiron 68 versus 20% C2F6 without other procedures³⁵⁵ for re-do surgery for persistent iFTMH; both were limited by a high risk of bias.

Research need

Trials of new procedures need to be designed and staged to consider learning curves and appropriate masking. The Idea/Innovation, Development, Exploration, Assessment, Long-term follow-up (IDEAL) framework should be considered.¹⁷⁷ Large scale RCTs on the role of adjuvants and other procedures on persistent iFTMH may be considered. Cases should be stratified by presenting vision, size of the hole and duration of symptoms and follow up should be for at least 6 months. National or international cooperation will be required to achieve the required sample sizes.

11b: Reopened iFTMH after initially successful primary surgery

Background

The success rate of vitrectomy for iFTMH is high, but there have been several series published outlining late reopening after successful closure, called 're-opened holes'. These are distinct from holes that don't close with primary surgery which have been described in Section 11a. The incidence of re-opened holes is unclear, with variable values reported in the literature as well as various risk factors for their occurrence proposed. The anatomical (macular hole closure) and functional (visual acuity improvement) success rate of surgery for re-opened holes has been suggested to be higher than that for persistent holes (i.e., iFTMH that do not close after the primary surgery).^{356,357,358}

Question 11.4: What is the rate of re-opening of MHs after successful MH surgery?

The proportion of eyes with reopening of iFTMH varies from 0.39% to 11%.^{194,265,350,356,358,359,360} Paques M, Massin P, Blain P, et al. Long-term incidence of reopening of macular holes. *Ophthalmology* 2000;107:760–766.

GRADE: MODERATE, SIGN Grade B

Question 11.5: Are there any surgical manoeuvres that reduce the rate of re-opening of MHs after successful MH surgery?

ILM peeling probably reduces the rate of MH reopening. The reopening rate without ILM peeling was estimated as 7.1%, compared with 1.2% with ILM peeling (odds ratio: 0.16; 95% CI 0.11–0.22).¹⁹⁴

GRADE: MODERATE, SIGN Grade B

Question 11.6: Are there other risk factors for re-opening after successful MH surgery?

No other consistent risk factors have been identified. Eyes with cystoid macular edema after cataract extraction following vitrectomy may have an increased risk of iFTMH reopening.^{194,265}

GRADE: LOW, SIGN Grade C

Summary of evidence

We identified two high quality systematic reviews, the most recent of which included 4 retrospective studies reporting 51 reopened holes of 1512 iFTMH undergoing surgery.³⁵⁰ The previous metanalysis included 50 largely retrospective studies of 5,480 macular hole surgeries.¹⁹⁴ The incidence rates are based on these two reviews and several other retrospective studies only. The rate in eyes that have undergone ILM peeling is substantially less than with ILM peeling (OR 0.16; 95%CI: 0.11–0.22; $p < 0.0001$). The second systematic review estimated the effect size of ILM peeling on preventing re-opening as stated above.

One other retrospective study²⁶⁵ of 211 patients that underwent iFTMH repair, with 61% having ILM peeling at the first surgery, divided patients into four groups: A pseudophakic group ($n=56$), a group that underwent cataract extraction after vitrectomy ($n=86$), a group that didn't require cataract extraction ($n=41$), and a group that had concurrent cataract extraction with vitrectomy for iFTMH ($n=28$). The overall reopening rate was 11% (24 eyes) with a mean follow up to 27 months (range 3–118). The highest rate of reopening occurred in the group with subsequent cataract surgery with a four-fold

increased rate of reopening (95% CI: 1.7 to 11.2; $p=0.002$). Eyes with cystoid macular oedema had a seven-fold increased risk of reopening. Other studies have not found the same association.

Question 11.7: How should iFTMH that reopen after successful closure be managed?

ILM should be peeled in revision surgery if not already performed.

GRADE: MODERATE, SIGN Grade B^{346,350,353,356} (A-D)

Other manoeuvres that have been tried are evaluated in the persistent macular hole section. There is insufficient evidence to manage re-opened holes differently and the evidence base for any of the many procedures recommended for persistent holes is not sufficient to make recommendations.

GRADE: LOW, SIGN Grade C^{238,239,346,353} (C-F)

Question 11.8: What are the results of surgery for reopened iFTMH?

Reopened holes can be successfully closed in approximately 80% of cases. The mean improvement from preoperative to postoperative levels is approximately 0.25 logMAR (~ 6/10 Snellen equivalent) with a gain of ≥ 2 Snellen line BCVA in approximately 75%. The closure rate is thus approximately the same as that for persistent holes but the visual results are marginally better (see persistent hole section).

GRADE: MODERATE, SIGN Grade B³⁵⁰ (A)

Summary of evidence

We identified one high quality systematic review (A) and the incidence rates are based on this review and several other retrospective studies. Reopened macular holes are rare when primary ILM peeling has been performed as is routinely done in many centres and hence management of these cases, as distinct from persistent holes is unclear with few published high-quality series.

12. Topical treatments for primary iFTMH, persistent and re-opened holes

Background

It has been suggested that topical treatments may be effective for some macular holes. The most accepted hypothesis of iFTMH formation is that they are secondary to tractional forces at the retinal surface. (See Section 2) However, there are cases of MH formation without evident traction and reported cases of MH formation post vitrectomy after relief of surface traction.³⁶³ A non-tractional pathophysiological mechanism was suggested by Tornambe, whereby a disruption in the integrity of the foveal surface allows fluid to enter the retina with resultant macular oedema and MH formation.⁶² Based on this hydration hypothesis, topical steroids, NSAIDs, and carbonic anhydrase inhibitors alone, or in any combination have been tried. Reports have mainly been made in persistent or re-opened holes, but there are a few also more recently in primary (i.e. naïve to treatment) MHs.^{364,365,366}

Question 12.1: Can primary iFTMH be treated successfully with topical treatment?

Some small iFTMH may be successfully closed with visual improvement with topical treatment only although the response rate and criteria predictive of a successful outcome are unclear.

GRADE: LOW, SIGN Grade C

Summary of evidence

We found 4 retrospective case series of less than 40 patients in total with primary iFTMH treated successfully with drops alone. They only reported successfully treated cases.^{364,365,366} (A–D) The 5th reported a consecutive series of 13 eyes of 13 patients who were offered topical treatment before surgery and treated over a 3-year period where 7/13 closed with topical treatment alone.³⁶⁸ (E) It is worth noting that 1 patient developed a fungal keratitis and 2/13 developed raised intraocular pressure. Generally, authors have noted that results are best in holes less than 200 microns with high baseline visual acuity, which are also positive predictive factors for spontaneous closure. A variety of drops regimes have been used.

Question 12.2: Can persistent or re-opened MHs be treated successfully with topical agents only?

Some re-opened and persistent holes may be successfully treated with drops only, although the response rate and criteria predictive of a successful outcome are unclear.

GRADE: VERY LOW, SIGN Grade D

Summary of evidence

There have been only anecdotal case reports and small series of both re-opened and persistent holes being successfully treated in terms of closure with topical agents. A variety of drops regimes have been used. Response rate to treatment, side effects and relapse are all unclear.^{369,370,371} (F–H)

Research need

The role of topical regimes in iFTMH both initially, prior to surgery, and in those cases with persistence or reopened holes needs to be explored in prospective interventional, preferably placebo controlled randomised trials.

Appendix 1

Section 6: Main evidence considered when making recommendations

- A. Chew EY, Sperduto RD, Hiller R, et al. Clinical course of macular holes: the Eye Disease Case-Control Study. *Archives of ophthalmology*. Feb 1999;117(2):242-6. doi:10.1001/archophth.117.2.242 **Grade 2+**
- B. Yuzawa M, Watanabe A, Takahashi Y, Matsui M. Observation of idiopathic full-thickness macular holes. Follow-up observation. *Archives of ophthalmology*. Aug 1994;112(8):1051-6. doi:10.1001/archophth.1994.01090200057022 **Grade 2+**
- C. Guyer DR, de Bustros S, Diener-West M, Fine SL. Observations on patients with idiopathic macular holes and cysts. *Archives of ophthalmology*. Sep 1992;110(9):1264-8 **Grade 2+**
- D. Parravano M, Giansanti F, Eandi CM, Yap YC, Rizzo S, Virgili G. Vitrectomy for idiopathic macular hole. *Cochrane database of systematic reviews (Online)*. May 12 2015;2015(5):Cd009080. doi:10.1002/14651858.CD009080.pub2 **Grade 1++**
- E. Jackson TL, Regillo CD, Girach A, Dugel PU, Group M-TS. Baseline Predictors of Vitreomacular Adhesion/Traction Resolution Following an Intravitreal Injection of Ocriplasmin. *Ophthalmic surgery, lasers & imaging retina*. Aug 1 2016;47(8):716-23. doi:10.3928/23258160-20160808-04 **Grade 1+**
- F. Haller JA, Stalmans P, Benz MS, et al. Efficacy of intravitreal ocriplasmin for treatment of vitreomacular adhesion: subgroup analyses from two randomized trials. *Ophthalmology*. Jan 2015;122(1):117-22. doi:10.1016/j.ophtha.2014.07.045 **Grade 1+**
- G. Dugel PU, Tolentino M, Feiner L, Kozma P, Leroy A. Results of the 2-Year Ocriplasmin for Treatment for Symptomatic Vitreomacular Adhesion Including Macular Hole (OASIS) Randomized Trial. *Ophthalmology*. Oct 2016;123(10):2232-47. doi:10.1016/j.ophtha.2016.06.04 **Grade 1+**
- H. Murphy DC, Al-Zubaidy M, Lois N, Scott N, Steel DH, Macular Hole Duration Study G. The Effect of Macular Hole Duration on Surgical Outcomes: An Individual Participant Data Study of Randomized Controlled Trials. *Ophthalmology*. Feb 2023;130(2):152-163. **Grade 1++**
- I. Jackson TL, Donachie PH, Sparrow JM, Johnston RL. United Kingdom National Ophthalmology Database study of vitreoretinal surgery: report 2, macular hole. *Ophthalmology*. Mar 2013;120(3):629-34. doi:10.1016/j.ophtha.2012.09.003 **Grade 2-**
- J. Steel DH, Donachie PHJ, Aylward GW, Laidlaw DA, Williamson TH, Yorston D. Factors affecting anatomical and visual outcome after macular hole surgery: findings from a large prospective UK cohort. *Eye*. Jan 2021;35(1):316-325. doi:10.1038/s41433-020-0844-x **Grade 2-**
- K. Neffendorf JE, Kirthi V, Pringle E, Jackson TL. Ocriplasmin for symptomatic vitreomacular adhesion. *Cochrane database of systematic reviews (Online)*. Oct 17 2017;10:CD011874. doi:10.1002/14651858.CD011874.pub2 **Grade 1++**
- L. Stalmans P, Delaey C, de Smet MD, van Dijkman E, Pakola S. Intravitreal injection of microplasmin for treatment of vitreomacular adhesion: results of a prospective, randomized, sham-controlled phase II trial (the MIVI-IIT trial). *Clinical Trial, Phase II Comparative Study Randomized Controlled Trial Research Support*. *Retina*. Jul-Aug 2010;30(7):1122-7. doi:10.1097/IAE.0b013e3181e0970a **Grade 1+**
- M. Stalmans P, Benz MS, Gandorfer A, et al. Enzymatic vitreolysis with ocriplasmin for vitreomacular traction and macular holes. *Clinical Trial, Phase III Comparative Study Multicenter Study Randomized Controlled Trial*. *New England journal of medicine*. Aug 16 2012;367(7):606-15. doi:10.1056/NEJMoa1110823 **Grade 1++**

- N.** Dugel PU, Tolentino M, Feiner L, Kozma P, Leroy A. Results of the 2-Year Ocriplasmin for Treatment for Symptomatic Vitreomacular Adhesion Including Macular Hole (OASIS) Randomized Trial. *Ophthalmology*. Oct 2016;123(10):2232-47. doi:10.1016/j.ophtha.2016.06.043 **Grade 1++**
- O.** Jackson TL, Haller J, Blot KH, Duchateau L, Lescauwae B. Ocriplasmin for treatment of vitreomacular traction and macular hole: A systematic literature review and individual participant data meta-analysis of randomized, controlled, double-masked trials. *Survey of ophthalmology*. Sep 2 2021;doi:10.1016/j.survophthal.2021.08.003 **Grade 1++**
- P.** Haynes RJ, Yorston D, Laidlaw DA, Keller J, Steel DH. Real world outcomes of ocriplasmin use by members of the British and Eire Association of Vitreoretinal Surgeons. *Eye*. Jan 2017;31(1):107-112. doi:10.1038/eye.2016.195 **Grade 2-**
- Q.** Chan CK, Mein CE, Glassman AR, et al. Pneumatic Vitreolysis with Perfluoropropane for Vitreomacular Traction with and without Macular Hole: DRCR Retina Network Protocols AG and AH. *Ophthalmology*. Nov 2021;128(11):1592-1603. doi:10.1016/j.ophtha.2021.05.005 **Grade 2-**
- R.** Quiroz-Reyes MA, Quiroz-Gonzalez EA, Quiroz-Gonzalez MA, Lima-Gomez V. Pneumatic vitreolysis versus vitrectomy for the treatment of vitreomacular traction syndrome and macular holes: complication analysis and systematic review with meta-analysis of functional outcomes. *Int J Retina Vitreous*. May 22 2023;9(1):33. doi:10.1186/s40942-023-00472-x **Grade 2-**

Section 7a: Main evidence considered when making recommendations

- A.** Wimpissinger B, Kellner L, Brannath W, Krepler K, Stolba U, Mihalics C, Binder S. 23-gauge versus 20-gauge system for pars plana vitrectomy: a prospective randomised clinical trial. *Br J Ophthalmol* 2008;92:1483-1487. doi:10.1136/bjo.2008.140509 **SIGN Grade 1-**
- B.** Scholz P, Müpothner PS, Schiller P, Felsch M, Fauser S. A Randomized Controlled Clinical Trial Comparing 20 Gauge and 23 Gauge Vitrectomy for Patients with Macular Hole or Macular Pucker *Adv Ther* (2018) 35:2152-2166 **SIGN Grade 1-**
- C.** Nam Y, Chung H, Lee JY, Kim JG, Yoon YH. Comparison of 25- and 23-gauge Sutureless microincision vitrectomy surgery in the treatment of various vitreoretinal diseases. *Eye* (2010) 24, 869-874 **SIGN Grade 1-**
- D.** Recchia FM, Scott IU, Brown GC, Brown MM, MD, Ho AC, Ip MS. Ophthalmic Technology Assessment. Small-Gauge Pars Plana Vitrectomy A Report by the American Academy of Ophthalmology. *Ophthalmology* 2010;117:1851-1857 **SIGN Grade 2++**
- E.** Shields RA, Ludwig CA, Powers MA, Tran EMT, Smith SJ, Moshfeghi. Postoperative Adverse Events, Interventions, and the Utility of Routine Follow-Up After 23-, 25-, and 27-Gauge Pars Plana Vitrectomy. *Asia Pac J Ophthalmol (Phila)* 2019;8:36-42 **SIGN Grade 2-**
- F.** Brown GT, Pugazhendhi S, Beardsley RM, Karth JW, Karth PA, Hunter AA. 25 vs. 27-gauge micro-incision vitrectomy surgery for visually significant macular membranes and full-thickness macular holes: a retrospective study. *Int J Retin Vitro* (2020) 6:56 **SIGN Grade 2-**
- G.** Rizzo S, Belting C, Genovesi-Ebert F, Di Bartolo E. Incidence of retinal detachment after small-incision, sutureless pars plana vitrectomy compared With conventional 20-gauge Vitrectomy in macular hole and Epiretinal membrane surgery *RETINA* 30:1065-1071, 2010 **SIGN Grade 2-**
- H.** Fujiwara N, Tomita G, Yagi F. Incidence and Risk Factors of Iatrogenic Retinal Breaks: 20-Gauge versus 25-Gauge Vitrectomy for Idiopathic Macular Hole Repair. *J Ophthalmol*. 2020 Feb 13;2020:5085180. **SIGN Grade 2-**

- I. Bahrani HM, Fazelat AA, Thomas M, Hirose T, Kroll AJ, Lou PL, Ryan EA. Endophthalmitis in the era of small gauge transconjunctival sutureless vitrectomy--meta analysis and review of literature. *Semin Ophthalmol*. 2010 Sep-Nov;25(5-6):275-82. **SIGN Grade 2++**
- J. Oshima Y, Kadonosono K, Yamaji H, Inoue M, Yoshida M, Kimura H, Ohji M, Shiraga F, Hamasaki T, On Behalf Of The Japan Microincision Vitrectomy Surgery Study Group. Multicenter Survey with a Systematic Overview of Acute-Onset Endophthalmitis after Transconjunctival Microincision Vitrectomy Surgery *Am J Ophthalmol* 2010;150:716-725 **SIGN Grade 2++**
- K. Govetto A, Virgili G, Menchini F, Lanzetta P, Menchini U. A systematic review of endophthalmitis after microincisional versus 20-gauge vitrectomy. *Ophthalmology*. 2013 Nov;120(11):2286-91. **SIGN Grade 2++**
- L. Bhende M, Raman R, Jain M, Shah PK, Sharma T, Gopal L, Bhende PS, Srinivasan S, Jambulingam M; Sankara Nethralaya Vitreoretinal Study Group (SNVR-Study Group). Incidence, microbiology, and outcomes of endophthalmitis after 111,876 pars plana vitrectomies at a single, tertiary eye care hospital. *PLoS One*. 2018 Jan 16;13(1):e0191173. **SIGN Grade 2-**
- M. Chen G, Tzekov R, Li W, Jiang F, Mao S, Tong Y. Incidence Of Endophthalmitis After Vitrectomy A Systematic Review and Meta-analysis 2019 *RETINA* 39:844-852. **SIGN Grade 2++**

Section 7b: Main evidence considered when making recommendations

- A. Christensen UC, Krøyer K, Sander B, et al. Value of internal limiting membrane peeling in surgery for idiopathic macular hole stage 2 and 3: a randomised clinical trial. *Br J Ophthalmol* 2009;93:1005-1015. **Grade 1+**
- B. Kwok AK, Lai TY, Wong VW. Idiopathic macular hole surgery in Chinese patients: a randomized study to compare indocyanine green assisted internal limiting membrane peeling with no internal limiting membrane peeling. *Hong Kong Medical Journal* 2005;11(4):259-66. **Grade 1-**
- C. Lois N, Burr J, Norrie J, et al. Internal limiting membrane peeling versus no peeling for idiopathic full-thickness macular hole: a pragmatic randomized controlled trial. *Invest Ophthalmol Vis Sci* 2011;52:1586-1592. **Grade 1++**
- D. Spiteri Cornish K, Lois N, Scott N, et al. Vitrectomy with internal limiting membrane (ILM) peeling versus vitrectomy with no peeling for idiopathic full-thickness macular hole (FTMH). *Cochrane Database Syst Rev* 2013;6:CD009306. **Grade 1++**
- E. Rahimy E, McCannel CA. Impact of internal limiting membrane peeling on macular hole reopening: a systematic review and meta-analysis. *Retina* 2016;36:679-687. **Grade 1-**
- F. Ternent L, Vale L, Boachie C, Burr JM, Lois N; Full-Thickness Macular Hole and Internal Limiting Membrane Peeling Study (FILMS) Group. Cost-effectiveness of internal limiting membrane peeling versus no peeling for patients with an idiopathic full-thickness macular hole: results from a randomised controlled trial. *Br J Ophthalmol*. 2012 Mar;96(3):438-43. doi: 10.1136/bjophthalmol-2011-300402. Epub 2011 Sep 6. PMID: 21900224. **Grade 1++**

Section 7c: Main evidence considered when making recommendations

- A.** Shukla D, Kalliath J, Neelakantan N, Naresh KB, Ramasamy K. A comparison of brilliant blue G, trypan blue, and indocyanine green dyes to assist internal limiting membrane peeling during macular hole surgery. *Retina*. 2011;31(10):2021–2025. doi:10.1097/IAE.0b013e318213618c. **Grade 2-**
- B.** Li SS, You R, Li M, Guo XX, Zhao L, Wang YL, Chen X. Internal limiting membrane peeling with different dyes in the surgery of idiopathic macular hole: a systematic review of literature and network Meta-analysis. *Int J Ophthalmol*. 2019 Dec 18;12(12):1917–1928. doi: 10.18240/ijo.2019.12.15. PMID: 31850178; PMCID: PMC6901880. **Grade 1-**
- C.** Modi A, Giridhar A, Gopalakrishnan M. Comparative analysis of outcomes with variable diameter internal limiting membrane peeling in surgery for idiopathic macular hole repair. *Retina*. 2017 Feb;37(2):265–273. doi: 10.1097/IAE.0000000000001123. PMID: 27429382. **Grade 1-**
- D.** Bae K, Kang SW, Kim JH, Kim SJ, Kim JM, Yoon JM. Extent of internal limiting membrane peeling and its impact on macular hole surgery outcomes: a Randomized Trial. *Am J Ophthalmol*. 2016;169:179–188. doi:10.1016/j.ajo.2016.06.041. **Grade 1-**
- E.** Sinawat S, Srihatrai P, Sutra P, Yospaiboon Y, Sinawat S. Comparative study of 1 DD and 2 DD radius conventional internal limiting membrane peeling in large idiopathic full-thickness macular holes: a randomized controlled trial. *Eye (Lond)*. 2021 Sep;35(9):2506–2513. doi: 10.1038/s41433-020-01259-2. Epub 2020 Nov 6. PMID: 33159177; PMCID: PMC8376962. **Grade 1+**
- F.** Khodabande A, Mahmoudi A, Faghihi H, Bazvand F, Ebrahimi E, Riazi-Esfahani H. Outcomes of Idiopathic Full-Thickness Macular Hole Surgery: Comparing Two Different ILM Peeling Sizes. *J Ophthalmol*. 2020 Aug 18;2020:1619450. doi: 10.1155/2020/1619450. PMID: 32908679; PMCID: PMC7450298. **Grade 1-**
- G.** Yao Y, Qu J, Dong C, Li X, Liang J, Yin H, Huang L, Li Y, Liu P, Pan C, Ding X, Song D, Sadda SR, Zhao M. The impact of extent of internal limiting membrane peeling on anatomical outcomes of macular hole surgery: results of a 54-week randomized clinical trial. *Acta Ophthalmol*. 2019 May;97(3):303–312. doi: 10.1111/aos.13853. Epub 2018 Sep 5. PMID: 30187641; PMCID: PMC6585771. **Grade 1-**
- H.** Ch'ng SW, Patton N, Ahmed M, Ivanova T, Baumann C, Charles S et al. The Manchester Large Macular Hole Study: Is it Time to Reclassify Large Macular Holes? *Am J Ophthalmol*. 2018; 195: 36–42. **Grade 2-**
- I.** Steel DH, Donachie PHJ, Aylward GW, Laidlaw DA, Williamson TH, Yorston D; BEAVRS Macular hole outcome group. Factors affecting anatomical and visual outcome after macular hole surgery: findings from a large prospective UK cohort. *Eye (Lond)*. 2021 Jan;35(1):316–325. doi: 10.1038/s41433-020-0844-x. Epub 2020 Mar 30. PMID: 32231259; PMCID: PMC7852599. **Grade 2-**
- J.** Michalewska Z, Michalewski J, Adelman RA, Nawrocki J. Inverted internal limiting membrane flap technique for large macular holes. *Ophthalmology*. 2010;117:2018–2025. **Grade 1-**
- K.** Velez-Montoya R, Ramirez-Estudillo JA, Sjolholm-Gomez de Liano C, et al. Inverted ILM flap, free ILM flap and conventional ILM peeling for large macular holes. *Int J Retina Vitreous*. 2018;4(1):8. **Grade 1-**
- L.** Manasa S, Kakkar P, Kumar A, Chandra P, Kumar V, Ravani R. Comparative Evaluation of Standard ILM Peel With Inverted ILM Flap Technique In Large Macular Holes: A Prospective, Randomized Study. *Ophthalmic Surg Lasers Imaging Retina*. 2018;49(4):236. **Grade 1-**

- M.** Kannan NB, Kohli P, Parida H, Adenuga OO, Ramasamy K. Comparative study of inverted internal limiting membrane (ILM) flap and ILM peeling technique in large macular holes: a randomized-control trial. *BMC Ophthalmol.* 2018;18(1):177. **Grade 1-**
- N.** Ghoraba H, Rittiphairoj T, Akhavanrezayat A, Karaca I, Matsumiya W, Pham B, Mishra K, Yasar C, Mobasserian A, Abdelkarem AA, Nguyen QD. Pars plana vitrectomy with internal limiting membrane flap versus pars plana vitrectomy with conventional internal limiting membrane peeling for large macular hole. *Cochrane Database Syst Rev.* 2023 Aug 7;8:CD015031. doi: 10.1002/14651858.CD015031.pub2. PMID: 37548231. **Grade 1++**

Section: 7c: Main evidence considered when making recommendations

- A.** Briand S, Chalifoux E, Tourville E, Bourgault S, Caissie M, Tardif Y, Giasson M, Boivin J, Blanchette C, Cinq-Mars B. Prospective randomized trial: outcomes of SF₆ versus C₃F₈ in macular hole surgery. *Can J Ophthalmol.* 2015 Apr;50(2):95-100. **Grade 1+**
- B.** Casini G, Loiudice P, De Cillà S, Radice P, Nardi M. Sulfur hexafluoride (SF₆) versus perfluoropropane (C₃F₈) tamponade and short-term face-down position for macular hole repair: a randomized prospective study. *Int J Retina Vitreous.* 2016 Apr 1;2:10. **Grade 1-**
- C.** Rishi P, Rishi E, Bhende P, Bhende M, Kandle K, Attiku Y, Roy KK, Shelke K, Madaan S; SNVR groups. A prospective, interventional study comparing the outcomes of macular hole surgery in eyes randomized to C₃F₈, C₂F₆, or SF₆ gas tamponade. *Int Ophthalmol.* 2022 May;42(5):1515-1521. **Grade1+**
- D.** Lindtjørn B, Krohn J, Haugstad M, Stene-Johansen I, Austeng D, Basit S, Fossen K, Varhaug P, Kvaløy JT, Forsaa VA. Air versus Sulfur Hexafluoride Gas Tamponade for Small and Medium-Sized Macular Holes: A Randomized Noninferiority Trial. *Ophthalmol Retina.* 2022 Sep;6(9):828-834. **Grade1+**
- E.** Veith M, Vránová J, Němčanský J, Studnička J, Penčák M, Straňák Z, Mojžíš P, Studený P, Piñero DP. Surgical Treatment of Idiopathic Macular Hole Using Different Types of Tamponades and Different Postoperative Positioning Regimens. *J Ophthalmol.* 2020 Dec 3;2020:8858317. **Grade1-**
- F.** Dervenis N, Dervenis P, Sandinha T, Murphy DC, Steel DH. Intraocular Tamponade Choice with Vitrectomy and Internal Limiting Membrane Peeling for Idiopathic Macular Hole: A Systematic Review and Meta-analysis. *Ophthalmol Retina.* 2022 Jun;6(6):457-468. **Grade1+**

Section: 7d: Main evidence considered in making recommendations

- 1.** Farahvash A, Popovic MM, Eshtiaghi A, Kertes PJ, Muni RH. Combined versus Sequential Phacoemulsification and Pars Plana Vitrectomy: A Meta-Analysis. *Ophthalmol Retina.* 2021 Nov;5(11):1125-1138. **SIGN Grade 2++**
- 2.** Daud F, Daud K, Popovic MM, Yeung S, You Y, Cruz Pimentel M, Yan P. Combined versus Sequential Pars Plana Vitrectomy and Phacoemulsification for Macular Hole and Epiretinal Membrane: A Systematic Review and Meta-Analysis. *Ophthalmol Retina.* 2023 Aug;7(8):721-731. **SIGN Grade 2++**
- 3.** Ahoor MH, Sorkhabi R, Eftekhari Milani A, Asghari Kaleibar S. Comparison of one step macular hole and cataract surgery with two step surgery. *Guoji Yanke Zazhi (Int Eye Sci)* 2016;16(10):1795-1799. **Grade 1-**
- 4.** Viana KÍS, Gordilho CT, Almeida FPP, Esperandio MM, Lucena DR, Garcia DM, Scott IU, Messias AMV, Jorge R. Combined pars plana vitrectomy (PPV) and phacoemulsification (phaco) versus PPV and deferred phaco for phakic patients with full-thickness macular hole (FTMH) and no significant

cataract at baseline: 1-year outcomes of a randomized trial combined PPV/phaco vs PPV/deferred phaco for MH. *Graefes Arch Clin Exp Ophthalmol*. 2021 Jan;259(1):29-36. **Grade 1-**

5. Savastano A, Lenzetti C, Finocchio L, Bacherini D, Giansanti F, Tartaro R, Piccirillo V, Savastano MC, Virgili G, Rizzo S. Combining cataract surgery with 25-gauge high-speed pars plana vitrectomy: A prospective study. *Eur J Ophthalmol*. 2021 Mar;31(2):673-678. **Grade 2+**
6. Muselier A, Dugas B, Buelle X, et al. Macular hole surgery and cataract extraction: combined vs consecutive surgery. *Am J Ophthalmol*. 2010;150(3):387-39. **Grade 2-**
7. Bhatnagar P, Kaiser PK, Smith SD, Meisler DM, Lewis H, Sears JE. Reopening of previously closed macular holes after cataract extraction. *Am J Ophthalmol*. 2007 Aug;144(2):252-9. **Grade 2-**
8. Wang Y, Liang X, Gao M, Liu J, Liu L, Liu W. Vision-related quality of life after pars plana vitrectomy with or without combined cataract surgery for idiopathic macular hole patients. *Int Ophthalmol*. 2019 Dec;39(12):2775-2783. **Grade 2+**
9. Lee JY, Kim K-H, Shin KH, Han DH, Lee DY, Nam DH. Comparison of intraoperative complications of phacoemulsification between sequential and combined procedures of pars plana vitrectomy and cataract surgery. *Retina*. 2012;32(10):2026-2033. **Grade 2-**
10. Patel D, Rahman R, Kumarasamy M. Accuracy of intraocular lens power estimation in eyes having phacovitrectomy for macular holes. *J Cataract Refract Surg*. 2007 Oct;33(10):1760-2. **Grade 2-**
11. Manvikar SR, Allen D, Steel DH. Optical biometry in combined phacovitrectomy. *J Cataract Refract Surg*. 2009 Jan;35(1):64-9. **Grade 2-**
12. Hamoudi H, La Cour M. Refractive changes after vitrectomy and phacovitrectomy for macular hole and epiretinal membrane. *J Cataract Refract Surg*. 2013 Jun;39(6):942-7. **Grade 2++**

Section 7e: Main Evidence Considered When Making Recommendations

- ⁹Tadayoni R, Vicaut E, Devin F, et al. A randomized controlled trial of alleviated positioning after small macular hole surgery. *Ophthalmology*. 2011;118:150e155 **SIGN Grade 1+**
- ¹²Alberti M, La Cour M. Gas-foveal contact: a new approach to evaluating positioning regimens in macular hole surgery. *Retina* 2018;38(5):913-21 **SIGN Grade 1+**
- ¹³Alberti M, la Cour M. Nonsupine positioning in macular hole surgery: a noninferiority randomized clinical trial. *Retina*. 2016;36:2072e2079 **SIGN Grade 1-**
- ¹⁴Guillaubey A, Malvitte L, Lafontaine PO, et al. Comparison of facedown and seated position after idiopathic macular hole surgery: a randomized clinical trial. *Am J Ophthalmol*. 2008;146:128e134. **SIGN Grade 1+**
- ¹⁵Lange CAK, Membrey L, Ahmad N, et al. Pilot randomized controlled trial of face-down positioning following macular hole surgery. *Eye (Lond)*. 2012;26:272e277. **SIGN Grade 1+**
- ¹⁶Pasu S, Bell L, Zenasni Z, et al. Facedown positioning following surgery for large full-thickness macular hole: a multicenter randomized clinical trial. *JAMA Ophthalmol*. 2020;138:725e730. **SIGN Grade 1+**
- ¹⁷Veith M, Vránová J, Nemcanský J, et al. Surgical treatment of idiopathic macular hole using different types of tamponades and different postoperative positioning regimens. *J Ophthalmol*. 2020;2020:8858317. **SIGN Grade 1+**
- ¹⁸Yorston D, Siddiqui MAR, Awan MA, et al. Pilot randomized controlled trial of face-down posturing following phacovitrectomy for macular hole. *Eye (Lond)*. 2012;26:267e271. **SIGN Grade 1+**
- ¹⁹Zhang Y, Chen X, Hong L, et al. Facedown positioning after vitrectomy will not facilitate macular hole closure based on swept-source optical coherence tomography imaging in gas-filled eyes: a prospective, randomized comparative interventional study. *Retina* 2019;39(12):2353-9. **SIGN Grade 1+**

- ²⁰ Chaudhary V, Sarohia GS, Phillips MR et al. Role of Positioning after Full-Thickness Macular Hole Surgery: A Systematic Review and Meta-Analysis. *Ophthalmol Retina*. 2023 Jan;7(1):33-43. Epub 2022 Jul 1. **SIGN Grade 1++**
- ²¹ Hu Z, Xie P, Ding Y, Zheng X, Yuan D, Liu Q. Face-down or no face-down posturing following macular hole surgery: a meta-analysis. *Acta Ophthalmol*. 2016 Jun;94(4):326-33. Epub 2015 Sep 19. **SIGN Grade 1+**
- ²² Xia S, Zhao XY, Wang EQ, Chen YX. Comparison of face-down posturing with nonsupine posturing after macular hole surgery: a meta-analysis. *BMC Ophthalmol*. 2019 Jan 28;19(1):34. **SIGN Grade 1+**
- ²³ Ye T, Yu JG, Liao L, Liu L, Xia T, Yang LL. Macular hole surgery recovery with and without face-down posturing: a meta-analysis of randomized controlled trials. *BMC Ophthalmol*. 2019 Dec 21;19(1):265. **SIGN Grade 1+**
- ²⁴ Tsai HR, Chen TL, Chang CY, Huang HK, Lee YC. Face-Down Posture versus Non-Face-Down Posture following Large Idiopathic Macular Hole Surgery: A Systemic Review and Meta-Analysis. *J Clin Med*. 2021 Oct 24;10(21):4895. **SIGN Grade 1+**
- ²⁵ Hu Z, Xie P, Ding Y, Zheng X, Yuan D, Liu Q. Face-down or no face-down posturing following macular hole surgery: a meta-analysis. *Acta Ophthalmol*. 2016 Jun;94(4):326-33. Epub 2015 Sep 19. **SIGN Grade 1+**

Section 9: Main evidence considered when making recommendations

Bheemidi AR, Roan VD, Muste JC, Singh RP. Examining the Necessity of Postoperative Day-1 Review After Pars Plana Vitrectomy: A Meta-Analysis. *Ophthalmic Surg Lasers Imaging Retina*. 2021 Sep;52(9):513-518. **Grade 2++**

Sciscio A, Casswell AG. Effectiveness of apraclonidine 1% in preventing intraocular pressure rise following macular hole surgery. *Br J Ophthalmol* 2001; 85(2): 164-168. **Grade 1-**

Benz MS, Escalona-Benz EM, Murray TG et al. Immediate postoperative use of a topical agent to prevent intraocular pressure elevation after pars plana vitrectomy with gas tamponade. *Arch Ophthalmol* 2004; 122(5): 705-709. **Grade 1-**

Wong R, Gupta B, Williamson TH, Laidlaw DA. Day 1 postoperative intraocular pressure spike in vitreoretinal surgery (VDOP1). *Acta Ophthalmol* 2011; 89(4): 365-368. **Grade 2+**

Brennan N, Reekie I, Ezra E, Barton K, Viswanathan A, Muqit MM. The role of day one postoperative review of intraocular pressure in modern vitrectomy surgery. *Br J Ophthalmol*. 2017 Sep;101(9):1281-1284. **Grade 2-**

Ringeisen AL, Parke DW 3rd. Reconsidering the Postoperative Day 0 Visit for Retina Surgery. *Ophthalmic Surg Lasers Imaging Retina*. 2018 Sep 1;49(9):e52-e56. **Grade 2-**

Alexander P, Michaels L, Newsom R. Is day-1 postoperative review necessary after pars plana vitrectomy? *Eye (Lond)*. 2015 Nov;29(11):1489-94. **Grade 2-**

Section 11a: Main evidence considered when making recommendations

A. Distelmaier P, Meyer LM, Fischer MT, Philipp S, Paquet P, Mammen A, Haller K, Schönfeld CL. Delayed macular hole closure. *Case Rep Ophthalmol*. 2014 Apr 10;5(1):121-4. **SIGN Grade 4**

B. Patel R, Gopalakrishnan M, Giridhar A. TIMING AND OUTCOME OF SURGERY FOR PERSISTENT MACULAR HOLE. *Retina*. 2019 Feb;39(2):314-318. **SIGN Grade 2-**

- C. Reid GA, McDonagh N, Wright DM, Yek JTO, Essex RW, Lois N. FIRST FAILED MACULAR HOLE SURGERY OR REOPENING OF A PREVIOUSLY CLOSED HOLE: Do We Gain by Reoperating? A Systematic Review and Meta-analysis. *Retina*. 2020 Jan;40(1):1-15. **SIGN Grade 2++**
- D. Yek JTO, Hunyor AP, Campbell WG, McAllister IL, Essex RW; Australian and New Zealand Society of Retinal Specialists Macular Hole Study Group. Outcomes of Eyes with Failed Primary Surgery for Idiopathic Macular Hole. *Ophthalmol Retina*. 2018 Aug;2(8):757-764. **SIGN Grade 2-**
- E. Baumann C, El-Faouri M, Ivanova T, Patton N, Ch'ng SW, Dhawahir-Scala F, Jalil A. MANCHESTER REVISIONAL MACULAR HOLE STUDY: Predictive Value of Optical Coherence Tomography Parameters on Outcomes of Repeat Vitrectomy, Extension of Internal Limiting Membrane Peel, and Gas Tamponade for Persistent Macular Holes. *Retina*. 2021 May 1;41(5):908-914. **SIGN Grade 2-**
- F. Chen, Y. Y. and C. M. Yang (2022). Intravitreal gas injection for early persistent macular hole after primary pars plana vitrectomy. *BMC Ophthalmology* 22(1): 369. **SIGN Grade 2-**
- G. J, Kraus J, Framme C, Jackson TL, Roider J, Gabel VP, Sachs HG. Retreatment of full-thickness macular hole: predictive value of optical coherence tomography. *Br J Ophthalmol*. 2007 Nov;91(11):1445-9. **SIGN Grade 2-**
- H. Lorenzi U, Mehech J, Caporossi T, Romano MR, De Fazio R, Parrat E, Matonti F, Mora P; ReMaHo Study Group. A retrospective, multicenter study on the management of macular holes without residual internal limiting membrane: the refractory macular hole (ReMaHo) study. *Graefes Arch Clin Exp Ophthalmol*. 2022 Dec;260(12):3837-3845. **SIGN Grade 2-**
- I. Maguire MJ, Steel DH, Yorston D, Hind J, El-Faouri M, Jalil A, Tyagi P, Wickham L, Laidlaw AH. OUTCOME OF REVISION PROCEDURES FOR FAILED PRIMARY MACULAR HOLE SURGERY. *Retina*. 2021 Jul 1;41(7):1389-1395. **SIGN Grade 2-**
- J. Szurman P, Wakili P, Stanzel BV, Siegel R, Boden KT, Rickmann A. Persistent macular holes - what is the best strategy for revision? *Graefes Arch Clin Exp Ophthalmol*. 2021 Jul;259(7):1781-1790. **SIGN Grade 2-**
- K. Frisina R, Gius I, Tozzi L, Midena E. Refractory full thickness macular hole: current surgical management. *Eye (Lond)*. 2022 Jul;36(7):1344-1354. **SIGN Grade 2-**
- L. Caporossi T, Tartaro R, Finocchio L, Pacini B, De Angelis L, Bacherini D, Rizzo S. HUMAN AMNIOTIC MEMBRANE TO TREAT MACULAR HOLES THAT FAILED TO CLOSE, SULFUR HEXAFLUORIDE ENDOTAMPONADE VERSUS AIR ENDOTAMPONADE: A Prospective Comparative Study. *Retina*. 2021 Apr 1;41(4):735-743. **SIGN Grade 1-**
- M. Cillino S, Cillino G, Ferraro LL, Casuccio A. TREATMENT OF PERSISTENTLY OPEN MACULAR HOLES WITH HEAVY SILICONE OIL (DENSIRON 68) VERSUS C2F6. A PROSPECTIVE RANDOMIZED STUDY. *Retina*. 2016 Apr;36(4):688-94. **SIGN Grade 1-**

Section 11b: Main evidence considered when making recommendations

- A. Reid GA, McDonagh N, Wright DM, Yek JTO, Essex RW, Lois N. FIRST FAILED MACULAR HOLE SURGERY OR REOPENING OF A PREVIOUSLY CLOSED HOLE: Do We Gain by Reoperating? A Systematic Review and Meta-analysis. *Retina*. 2020 Jan;40(1):1-15. **SIGN grade 2++**
- B. Kamyar Vaziri, Schwartz SG, Kishor KS, Fortun JA, Moshfeghi AA, Smiddy WE, Flynn JW Rates of Reoperation and Retinal Detachment after Macular Hole Surgery. *Ophthalmology* 2016;123:26-31. **SIGN Grade 2-**
- C. Kumagai K, Furukawa M, Ogino N, Larson E. Incidence and Factors Related to Macular Hole Reopening. *Am J Ophthalmol* 2010;149:127-132. **SIGN Grade 2-**
- D. Valldeperas X, Wong D. Is it worth reoperating on macular holes? *Ophthalmology*. 2008 Jan;115(1):158-63. **SIGN Grade 2-**

- E.** Abbey AM, Van Laere L, Shah AR, Hassan TS. Recurrent macular holes in the era of small-gauge vitrectomy: a review of incidence, risk factors, and outcomes. *Retina* 2017;37:921–924. **SIGN Grade 2-**
- F.** Paques M, Massin P, Blain P, et al. Long-term incidence of reopening of macular holes. *Ophthalmology* 2000;107:760–766. **SIGN Grade 2-**
- G.** Bhatnagar P, Kaiser PK, Smith SD, Meisler DM, Lewis H, Sears JE. Reopening of Previously Closed Macular Holes After Cataract Extraction. *Am J Ophthalmol* 2007;144:252–259. **SIGN Grade 2-**
- H.** Rahimy E, Mccannel CA. Impact of Internal Limiting Membrane Peeling on Macular Hole Reopening: A Systematic Review and Meta-Analysis. *Retina* 2016;36:679–687. **SIGN Grade 2++**

Section 12: Main evidence considered when making recommendations

- A.** Bonnell AC, Prenner S, Weinstein MS, Fine HF: Macular Hole Closure with Topical Steroids. *Retinal Cases & Brief Reports* 16:351–354, 2022. **SIGN Grade 3**
- B.** Richards PJ, Kulkarni AD, Nork TM, Leys M, Hinkle D, Conlin KA, Chang S, Chang JS: Nonsurgical Resolution of Full Thickness Macular Holes without Vitreomacular Traction. *Retin Cases Brief Rep.* 2023 Sep 1;17(5):584–587. **SIGN Grade 3**
- C.** Kokame GT, Johnson MW, Lim J, Flynn HW, de Carlo T, Yannuzzi N, Ryan EH, Omizo JN, Sridhar J, Staropoli P, Goldhagen B, Lian R: Closure of Full-Thickness Macular Holes Associated with Macular Edema with Medical Therapy. *Ophthalmologica* 2022;245:179–186. **SIGN Grade 3**
- D.** Kurz PA, Kurz DE. Macular hole closure and visual improvement with topical nonsteroidal treatment. *Arch Ophthalmol.* 2009 Dec;127(12):1687–8. **SIGN Grade 3**
- E.** Small KW, Avetisjan J, Shaya FS. Closure of Macular Holes With Topical Therapy. *J Vitreoretin Dis.* 2022 Dec 13;7(2):109–115. **SIGN Grade 2-**
- F.** Sokol JT, Schechet SA, Komati R, Elliott D, Vavvas DG, Kaplan RI, Ittiara ST, Farooq AV, Sheth VS, MacCumber MW, Ke R, Gentile RC, Skondra D. Macular Hole Closure with Medical Treatment. *Ophthalmol Retina.* 2021 Jul;5(7):711–713. **SIGN Grade 3**
- G.** Gonzalez-Saldivar G, Juncal V, Chow D. Topical steroids: A non-surgical approach for recurrent macular holes. *Am J Ophthalmol Case Rep.* 2018 Dec 18;13:93–95. **SIGN Grade 3**
- H.** Khurana RN, Wieland MR. Topical Steroids for Recurrent Macular Hole after Pars Plana Vitrectomy. *Ophthalmol Retina.* 2018 Jun;2(6):636–637. **SIGN Grade 3**

Appendix 2

QUESTION 2a

MEDLINE

1. Retinal Perforations/
2. (macula\$ adj2 hole\$.tw.
3. or/1-2
4. (vitreomacular adj3 (adhesion\$ or traction\$)).tw.
5. VMT.tw.
6. Vitreous Detachment/
7. (vitreous adj2 detach\$.tw.
8. (etiolog\$ or aetiolog\$.tw.
9. or/4-8
10. 3 and 9
11. exp case reports/
12. (case adj2 report\$.tw.
13. or/11-12
14. 10 not 13
15. limit 14 to english language
16. limit 15 to yr="2000 -Current"
17. (vitrectom\$ or peeling or perfluoropropane or gas or tamponade or endotamponade or gauge).ti.
18. (limiting adj1 membrane).ti.
19. fellow.ti.
20. Ocriplasmin.ti.
21. or/17-20
22. 16 not 21
23. limit 22 to (comment or editorial or letter)
24. 22 not 23

Embase

1. retina macula hole/
 2. (macula\$ adj2 hole\$.tw.
 3. or/1-2
 4. (vitreomacular adj3 (adhesion\$ or traction\$)).tw.
 5. VMT.tw.
 6. vitreous body detachment/
 7. (vitreous adj2 detach\$.tw.
 8. (etiolog\$ or aetiolog\$.tw.
 9. or/4-8
 10. 3 and 9
 11. exp case report/
 12. (case adj2 report\$.tw.
 13. or/11-12
 14. 10 not 13
 15. limit 14 to english language
 16. limit 15 to yr="2000 -Current"
-

17. (vitrectom\$ or peeling or perfluoropropane or gas or tamponade or endotamponade or gauge).ti.
18. (limiting adj1 membrane).ti.
19. fellow.ti.
20. Ocriplasmin.ti.
21. or/17-20
22. 16 not 21
23. limit 22 to conference abstract status
24. 22 not 23
25. limit 24 to (editorial or letter or note)
26. 24 not 25

QUESTION 2b

MEDLINE

1. Retinal Perforations/
2. (macula\$ adj2 hole\$.tw.
3. or/1-2
4. exp Myopia/
5. myopia.tw.
6. Hyperopia/
7. hyperopi\$.tw.
8. eye injuries/ or eye injuries, penetrating/
9. (eye\$ or ocular).tw.
10. (injur\$ or trauma\$ or wound\$.tw.
11. 9 and 10
12. idiopathic.tw.
13. (female\$ or gender\$.tw.
14. Age Factors/ or "Age of Onset"/
15. 4 or 5 or 6 or 7 or 8 or 11 or 12 or 13 or 14
16. risk factors/
17. risk\$.tw.
18. 16 or 17
19. 3 and 15 and 18
20. exp case reports/
21. (case adj2 report\$.tw.
22. or/20-21
23. 19 not 22
24. limit 23 to english language
25. limit 24 to yr="2000 -Current"
26. (peeling or perfluoropropane or gas or tamponade or endotamponade or gauge).ti.
27. (limiting adj1 membrane).ti.
28. 26 or 27
29. 25 not 28

Embase

1. Retina Macula Hole/
2. (macula\$ adj2 hole\$.tw.
3. or/1-2

4. exp myopia/
5. myopia.tw.
6. hypermetropia/
7. hyperopi\$.tw.
8. eye injury/
9. (eye\$ or ocular).tw.
10. (injur\$ or trauma\$ or wound\$).tw.
11. 9 and 10
12. idiopathic.tw.
13. (female\$ or gender\$).tw.
14. age/
15. 4 or 5 or 6 or 7 or 8 or 11 or 12 or 13 or 14
16. risk factor/
17. risk\$.tw.
18. 16 or 17
19. 3 and 15 and 18
20. exp case report/
21. (case adj2 report\$).tw.
22. or/20-21
23. 19 not 22
24. limit 23 to english language
25. limit 24 to conference abstract status
26. 24 not 25
27. limit 26 to yr="2000 -Current"
28. (peeling or perfluoropropane or gas or tamponade or endotamponade or gauge).ti.
29. (limiting adj1 membrane).ti.
30. 28 or 29
31. 27 not 30

QUESTION 2c

MEDLINE

1. Retinal Perforations/
2. (macula\$ adj2 (hole\$ or break or tear)).tw.
3. or/1-2
4. (fellow adj2 eye\$).tw.
5. 3 and 4
6. case reports/
7. (case adj2 report\$).tw.
8. or/6-7
9. 5 not 8
10. limit 9 to english language
11. limit 10 to yr="2000 -Current"

Embase

1. Retina Macula Hole/
2. (macula\$ adj2 (hole\$ or break or tear)).tw.
3. or/1-2

4. (fellow adj2 eye\$).tw.
5. 3 and 4
6. case report/
7. (case adj2 report\$).tw.
8. or/6-7
9. 5 not 8
10. limit 9 to conference abstract status
11. 9 not 10
12. limit 11 to english language
13. limit 12 to yr="2000 -Current"

QUESTION 3 a,b,c

MEDLINE

1. Retinal Perforations/
2. (macula\$ adj2 (hole\$ or break or tear)).tw.
3. or/1-2
4. Surgery, Computer-Assisted/
5. Computer User Training/
6. Computer Simulation/
7. Computer-Assisted Instruction/
8. Imaging, Three-Dimensional/
9. 3D.tw.
10. heads-up.tw.
11. (digital\$ adj2 assist\$ adj2 vitreoretinal).tw.
12. (train\$ or education\$ or tutorial).tw.
13. (virtual\$ or simulat\$).tw.
14. Telemedicine/
15. (telemedicine or tele-educat\$).tw.
16. exp Education, Medical/
17. Teaching/
18. Inservice Training/
19. Physician's Practice Patterns/
20. Professional Practice/
21. Professional Competence/
22. Clinical Competence/
23. "Surveys and Questionnaires"/
24. (skill\$ or competenc\$ or supervision).tw.
25. ((trainee or experienced or performance) adj3 (surgical or surgeon\$ or ophthalmologist\$ or member\$)).tw.
26. (residenc\$ or resident\$ or curriculum).tw.
27. Ophthalmologists/ec, ed, og, st, sn, sd, td [Economics, Education, Organization & Administration, Standards, Statistics & Numerical Data, Supply & Distribution, Trends]
28. Ophthalmology/ec, ed, mt, og, st, sn, sd, td [Economics, Education, Methods, Organization & Administration, Standards, Statistics & Numerical Data, Supply & Distribution, Trends]
29. (facilities or equipment).tw.
30. or/4-29

31. 3 and 30
32. case reports/
33. (case adj2 report\$).tw.
34. or/32-33
35. 31 not 34
36. limit 35 to english language
37. limit 36 to yr="2000 -Current"

Embase

1. Retina Macula Hole/
2. (macula\$ adj2 (hole\$ or break or tear)).tw.
3. or/1-2
4. computer assisted surgery/
5. three-dimensional imaging/
6. computer simulation/
7. human computer interaction/
8. 3D.tw.
9. heads-up.tw.
10. (digital\$ adj2 assist\$ adj2 vitreoretinal).tw.
11. (virtual\$ or simulat\$).tw.
12. (train\$ or education\$ or tutorial).tw.
13. Telemedicine/
14. (telemedicine or tele-educat\$).tw.
15. medical education/
16. Teaching/
17. In service Training/
18. clinical practice/
19. professional practice/
20. professional competence/
21. clinical competence/
22. questionnaire/
23. (residenc\$ or resident\$ or curriculum\$).tw.
24. (skill\$ or competenc\$ or supervision).tw.
25. ((trainee or experienced or performance) adj3 (surgical or surgeon\$ or ophthalmologist\$ or member\$)).tw.
26. (facilities or equipment).tw.
27. or/4-26
28. 3 and 27
29. case report/
30. (case adj2 report\$).tw.
31. or/29-30
32. 28 not 31
33. limit 32 to english language
34. limit 33 to conference abstract status
35. 33 not 34
36. limit 35 to yr="2000 -Current"

QUESTION 4a

MEDLINE

1. Retinal Perforations/
2. (macula\$ adj2 (hole\$ or break or tear)).tw.
3. or/1-2
4. Tomography, optical coherence/
5. Tomography/
6. (optical\$ adj2 coherence\$ adj2 tomograph\$).tw.
7. Computed Tomography Angiography/
8. (HD-OCT or SD-OCT or OCT-A or SS-OCTA or SD-OCTA).tw.
9. (angioplex or cirrus or spectralis or stratus or rtvue).tw.
10. or/4-9
11. ((fundus or fundal) adj2 (photograph\$ or camera or image or imaging)).tw.
12. fundus autofluorescence.tw.
13. 11 or 12
14. 3 and 10 and 13
15. case reports/
16. (case adj2 report\$).tw.
17. or/15-16
18. 14 not 17
19. limit 18 to english language
20. limit 19 to yr="2000 - 2022"

Embase

1. retina macula hole/
2. (macula\$ adj2 (hole\$ or break or tear)).tw.
3. or/1-2
4. optical coherence tomography/
5. tomography/
6. (optical\$ adj2 coherence\$ adj2 tomograph\$).tw.
7. optical coherence tomography - scanning laser ophthalmoscope/
8. computed tomographic angiography/
9. (HD-OCT or SD-OCT or OCT-A or SS-OCTA or SD-OCTA).tw.
10. (angioplex or cirrus or spectralis or stratus or rtvue).tw.
11. or/4-10
12. ((fundus or fundal) adj2 (photograph\$ or camera or image or imaging)).tw.
13. fundus autofluorescence.tw.
14. 12 or 13
15. 3 and 11 and 14
16. case report/
17. (case adj2 report\$).tw.
18. or/16-17
19. 15 not 18
20. limit 19 to english language
21. limit 20 to yr="2000 - 2022"

22. limit 21 to conference abstract status
23. 21 not 22

QUESTION 4b,4c

MEDLINE

1. Retinal Perforations/
2. (macula\$ adj2 (hole\$ or break or tear)).tw.
3. or/1-2
4. "Referral and Consultation"/
5. (referral\$ or referred or referable).tw.
6. (consultation\$ or appointment\$).tw.
7. (care adj4 pathway\$).tw.
8. or/4-7
9. 3 and 8
10. case reports/
11. (case adj2 report\$).tw.
12. or/10-11
13. 9 not 12
14. limit 13 to english language
15. limit 14 to yr="2000 -Current"

Embase

1. Retina Macula Hole/
2. (macula\$ adj2 (hole\$ or break or tear)).tw.
3. or/1-2
4. patient referral/
5. consultation/
6. (referral\$ or referred or referable).tw.
7. (consultation\$ or appointment\$).tw.
8. (care adj4 pathway\$).tw.
9. or/4-8
10. 3 and 9
11. limit 10 to english language
12. limit 11 to yr="2000 -Current"
13. limit 12 to conference abstract status
14. 12 not 13
15. case report/
16. (case adj2 report\$).tw.
17. or/15-16
18. 14 not 17

Patient referral questions Q4d, Q8d, Q10d

MEDLINE

1. Retinal Perforations/
2. (macula\$ adj2 (hole\$ or break or tear)).tw.
3. or/1-2

4. Patient Education as Topic/
5. patient education handout/
6. (patient\$ adj3 (educat\$ or information)).tw.
7. (counseling or counselor).tw.
8. Treatment Refusal/
9. (patient\$ adj3 (refus\$ or declin\$)).tw.
10. or/4-9
11. 3 and 10
12. exp case reports/
13. (case adj2 report\$).tw.
14. or/12-13
15. 11 not 14
16. limit 15 to english language
17. limit 16 to yr="2000 -Current"

Embase

1. retina macula hole/
2. (macula\$ adj2 (hole\$ or break or tear)).tw.
3. or/1-2
4. patient education/
5. patient engagement/
6. (patient\$ adj3 (educat\$ or information)).tw.
7. (counseling or counselor).tw.
8. treatment refusal/
9. (patient\$ adj3 (refus\$ or declin\$)).tw.
10. or/4-9
11. 3 and 10
12. exp case report/
13. (case adj2 report\$).tw.
14. or/12-13
15. 11 not 14
16. limit 15 to english language
17. limit 16 to yr="2000 -Current"

QUESTION 5a

MEDLINE

1. Retinal Perforations/
2. (macula\$ adj2 (hole\$ or break or tear)).tw.
3. or/1-2
4. exp disease progression/
5. ("stage 1" or "stage 2" or "stage 3" or "stage 4").tw.
6. (staging or classific\$).tw.
7. (anatom\$ adj1 defin\$).tw.
8. (nomenclature or standardize or standardise).tw.
9. (OCT adj2 (diagnos\$ or management)).tw.
10. or/4-9

11. 3 and 10
12. case reports/
13. (case adj2 report\$).tw.
14. or/12-13
15. 11 not 14
16. limit 15 to english language
17. limit 16 to yr="2000 -Current"

Embase

1. Retina Macula Hole/
2. (macula\$ adj2 (hole\$ or break or tear)).tw.
3. or/1-2
4. disease classification/
5. disease exacerbation/
6. ("stage 1" or "stage 2" or "stage 3" or "stage 4").tw.
7. (staging or classif\$).tw.
8. (anatom\$ adj1 defin\$).tw.
9. (nomenclature or standardize or standardise).tw.
10. (OCT adj2 (diagnos\$ or management)).tw.
11. or/4-10
12. 3 and 11
13. case report/
14. (case adj2 report\$).tw.
15. or/13-14
16. 12 not 15
17. limit 16 to conference abstract status
18. 16 not 17
19. limit 18 to english language
20. limit 19 to yr="2000 - 2023"

QUESTION 5b

MEDLINE

1. Retinal Perforations/
2. (macula\$ adj2 (hole\$ or break or tear)).tw.
3. or/1-2
4. observation.tw.
5. (wait\$ or watch\$).tw.
6. (resolution adj10 hole\$).tw.
7. (spontaneous\$ adj2 (close\$ or closure)).tw.
8. (no adj1 (surgery or surgical)).tw.
9. or/4-8
10. 3 and 9
11. exp case reports/
12. (case adj2 report\$).tw.
13. or/11-12
14. 10 not 13

15. limit 14 to english language
16. limit 15 to yr="2000 -Current"

Embase

1. Retina Macula Hole/
2. (macula\$ adj2 (hole\$ or break or tear)).tw.
3. or/1-2
4. observation.tw.
5. (wait\$ or watch\$).tw.
6. (spontaneous\$ adj2 (close\$ or closure)).tw.
7. (resolution adj10 hole\$).tw.
8. (no adj1 (surgery or surgical)).tw.
9. or/4-8
10. 3 and 9
11. case report/
12. (case adj2 report\$).tw.
13. or/11-12
14. 10 not 13

QUESTION 6a

Cochrane Library

- #1 MeSH descriptor: [Retinal Perforations] this term only
- #2 macula* NEAR/2 (hole* or break or tear)
- #3 #1 or #2
- #4 MeSH descriptor: [Vitrectomy] this term only
- #5 vitrectom*
- #6 PPV*
- #7 MeSH descriptor: [Fibrinolysin] this term only
- #8 MeSH descriptor: [Fibrinolytic Agents] this term only
- #9 MeSH descriptor: [Proteolysis] this term only
- #10 MeSH descriptor: [Peptide Fragments] this term only
- #11 ocriplasmin* or Jetrea* or Microplasmin*
- #12 MeSH descriptor: [Endotamponade] this term only
- #13 MeSH descriptor: [Fluorocarbons] this term only
- #14 MeSH descriptor: [Sulfur Hexafluoride] explode all trees
- #15 sulfu* hexafluoride*
- #16 hexafluoroethane*
- #17 perfluoropropane*
- #18 octafluoropropane*
- #19 SF6 or C2F6 or C3F8
- #20(gas or air) NEAR/2 (endotamponade or tamponade)
- #21 vitreolysis
- #22#4 or #5 or #6 or #7 or #8 or #9 or #10 or #11 or #14 or #15 or #16 or #17 or #18 or #19 or #20 or #21
- #23#3 and #22

MEDLINE

1. comparative study/
2. controlled clinical trial/
3. control groups/
4. cross-over studies/
5. single-blind method/
6. double-blind method/
7. exp randomized controlled trial/
8. random allocation/
9. meta-analysis/
10. network meta-analysis/
11. "systematic review"/
12. controlled clinical trials as topic/
13. randomized controlled trials as topic/
14. meta-analysis as topic/
15. (compare\$ or control\$ or group or groups or versus or interventional or noninferior\$ or equivalence or random\$).tw.
16. or/1-15
17. Retinal Perforations/
18. (macula\$ adj2 (hole\$ or break or tear)).tw.
19. 17 or 18
20. vitrectomy/
21. vitrectom\$.tw.
22. PPV\$.tw.
23. Fibrinolysin/
24. Fibrinolytic Agents/
25. Proteolysis/
26. Peptide Fragments/
27. (ocriplasmin\$ or Jetrea\$ or Microplasmin\$).tw.
28. Endotamponade/
29. Fluorocarbons/
30. sulfur hexafluoride/
31. sulfu\$ hexafluoride\$.tw.
32. hexafluoroethane\$.tw.
33. perfluoropropane\$.tw.
34. octafluoropropane\$.tw.
35. (SF6 or C2F6 or C3F8).tw.
36. ((gas or air) adj2 (endotamponade or tamponade)).tw.
37. vitreolysis.tw.
38. or/20-37
39. 19 and 38
40. 16 and 39

Embase

1. Retina Macula Hole/
2. (macula\$ adj2 (hole\$ or break or tear)).tw.
3. 1 or 2

4. exp vitrectomy/
5. vitrectom\$.tw.
6. PPV\$.tw.
7. ocriplasmin/
8. fibrinolytic agent/
9. peptide fragment/
10. (ocriplasmin\$ or Jetrea\$ or Microplasmin\$).tw.
11. Endotamponade/
12. sulfur hexafluoride/
13. sulfu\$ hexafluoride\$.tw.
14. hexafluoroethane\$.tw.
15. fluorocarbon/
16. dimeticone/
17. perfluoropropane\$.tw.
18. polydimethylsiloxane\$.tw.
19. perfluoro-n-octane.tw.
20. ((gas or air) adj2 (endotamponade or tamponade)).tw.
21. (SF6 or C2F6 or C3F8).tw.
22. vitreolysis.tw.
23. or/4-22
24. 3 and 23

QUESTION 6b, 6c

Cochrane Library

- #1 MeSH descriptor: [Retinal Perforations] this term only
- #2 macula* NEAR/2 (hole* or break or tear)
- #3 #1 OR #2
- #4 MeSH descriptor: [Vitrectomy] explode all trees
- #5 vitrectom*
- #6 PPV*
- #7 #4 OR #5 OR #6
- #8 20 near/3 gauge
- #9 23 near/3 gauge
- #10 25 near/3 gauge
- #11 #8 OR #9 OR #10
- #12 #7 AND #11
- #13 #3 AND #12

MEDLINE

1. comparative study/
2. controlled clinical trial/
3. control groups/
4. cross-over studies/
5. single-blind method/
6. double-blind method/
7. exp randomized controlled trial/

8. random allocation/
9. meta-analysis/
10. network meta-analysis/
11. "systematic review"/
12. controlled clinical trials as topic/
13. randomized controlled trials as topic/
14. meta-analysis as topic/
15. (compare\$ or control\$ or group or groups or versus or interventional or noninferior\$ or equivalence or random\$).tw.
16. or/1-15
17. Retinal Perforations/
18. (macula\$ adj2 (hole\$ or break or tear)).tw.
19. 17 or 18
20. vitrectomy/
21. vitrectom\$.tw.
22. PPV\$.tw.
23. or/20-22
24. ("20" adj3 gauge).tw.
25. ("23" adj3 gauge).tw.
26. ("25" adj3 gauge).tw.
27. or/24-26
28. 23 and 27
29. 16 and 19 and 28

Embase

1. comparative study/
2. controlled clinical trial/
3. control group/
4. crossover procedure/
5. single blind procedure/
6. double blind procedure/
7. exp randomized controlled trial/
8. randomization/
9. meta-analysis/
10. network meta-analysis/
11. "systematic review"/
12. "controlled clinical trial (topic)"/
13. "randomized controlled trial (topic)"/
14. "meta analysis (topic)"/
15. "systematic review (topic)"/
16. (compare\$ or control\$ or group or groups or versus or interventional or noninferior\$ or equivalence or random\$).tw.
17. or/1-16
18. Retina Macula Hole/
19. (macula\$ adj2 (hole\$ or break or tear)).tw.
20. 18 or 19
21. exp vitrectomy/

22. vitrectom\$.tw.
23. PPV\$.tw.
24. or/21-23
25. ("20" adj3 gauge).tw.
26. ("23" adj3 gauge).tw.
27. ("25" adj3 gauge).tw.
28. or/25-27
29. 24 and 28
30. 17 and 20 and 29

QUESTION 6d, 6e

Cochrane Library

- #1 MeSH descriptor: [Retinal Perforations] this term only
- #2 macula* NEAR/2 (hole* OR break OR tear)
- #3 #1 OR #2
- #4 MeSH descriptor: [Vitrectomy] this term only
- #5 vitrectom*
- #6 PPV*
- #7 #4 OR #5 OR #6
- #8 MeSH descriptor: [Epiretinal Membrane] this term only
- #9 MeSH descriptor: [Basement Membrane] this term only
- #10 internal NEAR/2 limit* NEAR/2 membrane*
- #11 ILM
- #12 peel*
- #13 MeSH descriptor: [Surgical Flaps] this term only
- #14 flap
- #15 MeSH descriptor: [Indocyanine Green] this term only
- #16 MeSH descriptor: [Rosaniline Dyes] this term only
- #17 (infracyanine OR indocyanine) NEAR/1 green
- #18 (brilliant OR trypan) NEAR/1 blue
- #19 BBG OR ICG
- #20 MeSH descriptor: [Fovea Centralis] this term only
- #21 fovea* NEAR/2 spar*
- #22 membrane NEAR/2 scraper
- #23 forcep*
- #24 finesse NEAR/1 flex NEAR/1 loop
- #25 #8 OR #9 OR #10 OR #11 OR #12 OR #13 OR #14 OR #15 OR #16 OR #17 OR #18 OR #19 OR #20 OR #21 OR #22 OR #23 OR #24
- #26 #3 AND #7 AND #25

MEDLINE

1. comparative study/
2. controlled clinical trial/
3. control groups/
4. cross-over studies/
5. single-blind method/
6. double-blind method/

7. exp randomized controlled trial/
8. random allocation/
9. meta-analysis/
10. network meta-analysis/
11. "systematic review"/
12. controlled clinical trials as topic/
13. randomized controlled trials as topic/
14. meta-analysis as topic/
15. (compare\$ or control\$ or group or groups or versus or interventional or noninferior\$ or equivalence or random\$).tw.
16. or/1-15
17. Retinal Perforations/
18. (macula\$ adj2 (hole\$ or break or tear)).tw.
19. 17 or 18
20. vitrectomy/
21. vitrectom\$.tw.
22. PPV\$.tw.
23. or/20-22
24. Epiretinal Membrane/
25. Basement Membrane/
26. (internal adj2 limit\$ adj2 membrane\$).tw.
27. ILM.tw.
28. peel\$.tw.
29. Surgical Flaps/
30. flap.tw.
31. Indocyanine Green/
32. Rosaniline Dyes/
33. ((brilliant or trypan) adj1 blue).tw.
34. BBG.tw.
35. ((infracyanine or indocyanine) adj1 green).tw.
36. ICG.tw.
37. Fovea Centralis/
38. (fovea\$ adj2 spar\$).tw.
39. (membrane adj2 scraper).tw.
40. forcep\$.tw.
41. (finesse adj1 flex adj1 loop).tw.
42. or/24-41
43. 16 and 19 and 23 and 42

Embase

1. comparative study/
2. controlled clinical trial/
3. control group/
4. crossover procedure/
5. single blind procedure/
6. double blind procedure/
7. exp randomized controlled trial/

8. randomization/
9. meta-analysis/
10. network meta-analysis/
11. "systematic review"/
12. "controlled clinical trial (topic)"/
13. "randomized controlled trial (topic)"/
14. "meta analysis (topic)"/
15. "systematic review (topic)"/
16. (compare\$ or control\$ or group or groups or versus or interventional or noninferior\$ or equivalence or random\$).tw.
17. or/1-16
18. Retina Macula Hole/
19. (macula\$ adj2 (hole\$ or break or tear)).tw.
20. 18 or 19
21. exp vitrectomy/
22. vitrectom\$.tw.
23. PPV\$.tw.
24. or/21-23
25. epiretinal membrane/
26. basement membrane/
27. (internal adj2 limit\$ adj2 membrane\$).tw.
28. ILM.tw.
29. peel\$.tw.
30. surgical flaps/
31. flap.tw.
32. indocyanine green/
33. trypan blue/
34. brilliant blue/
35. ((infracyanine or indocyanine) adj1 green).tw.
36. ((brilliant or trypan) adj1 blue).tw.
37. (BBG or ICG).tw.
38. retina fovea/
39. (fovea\$ adj2 spar\$).tw.
40. (membrane adj2 scraper).tw.
41. forcep\$.tw.
42. (finesse adj1 flex adj1 loop).tw.
43. or/25-42
44. 17 and 20 and 24 and 43

QUESTION 6f

Cochrane Library

- #1 MeSH descriptor: [Retinal Perforations] this term only
- #2 macula* NEAR/2 (hole* or break or tear)
- #3 #1 or #2
- #4 MeSH descriptor: [Vitrectomy] this term only
- #5 vitrectom*

- #6 PPV*
- #7 #4 or #5 or #6
- #8 MeSH descriptor: [Endotamponade] this term only
- #9 MeSH descriptor: [Fluorocarbons] this term only
- #10 MeSH descriptor: [Sulfur Hexafluoride] this term only
- #11 sulfu* hexafluoride*
- #12 hexafluoroethane*
- #13 perfluoropropane*
- #14 polydimethylsiloxane*
- #15 perfluoro-n-octane
- #16 (gas or air) NEAR/2 (endotamponade or tamponade)
- #17 SF6 or C2F6 or C3F8
- #18 #8 or #9 or #10 or #11 or #12 or #13 or #14 or #15 or #16 or #17
- #19 #3 and #7 and #18

MEDLINE

- 1. comparative study/
- 2. controlled clinical trial/
- 3. control groups/
- 4. cross-over studies/
- 5. single-blind method/
- 6. double-blind method/
- 7. exp randomized controlled trial/
- 8. random allocation/
- 9. meta-analysis/
- 10. network meta-analysis/
- 11. "systematic review"/
- 12. controlled clinical trials as topic/
- 13. randomized controlled trials as topic/
- 14. meta-analysis as topic/
- 15. (compare\$ or control\$ or group or groups or versus or interventional or noninferior\$ or equivalence or random\$.tw.
- 16. or/1-15
- 17. Retinal Perforations/
- 18. (macula\$ adj2 (hole\$ or break or tear)).tw.
- 19. 17 or 18
- 20. vitrectomy/
- 21. vitrectom\$.tw.
- 22. PPV\$.tw.
- 23. or/20-22
- 24. Endotamponade/
- 25. Fluorocarbons/
- 26. sulfur hexafluoride/
- 27. sulfu\$ hexafluoride\$.tw.
- 28. hexafluoroethane\$.tw.
- 29. perfluoropropane\$.tw.
- 30. polydimethylsiloxane\$.tw.

31. perfluoro-n-octane.tw.
32. ((gas or air) adj2 (endotamponade or tamponade)).tw.
33. (SF6 or C2F6 or C3F8).tw.
34. or/24-33
35. 16 and 19 and 23 and 34

Embase

1. comparative study/
2. controlled clinical trial/
3. control group/
4. crossover procedure/
5. single blind procedure/
6. double blind procedure/
7. exp randomized controlled trial/
8. randomization/
9. meta-analysis/
10. network meta-analysis/
11. "systematic review"/
12. "controlled clinical trial (topic)"/
13. "randomized controlled trial (topic)"/
14. "meta analysis (topic)"/
15. "systematic review (topic)"/
16. (compare\$ or control\$ or group or groups or versus or interventional or noninferior\$ or equivalence or random\$).tw.
17. or/1-16
18. Retina Macula Hole/
19. (macula\$ adj2 (hole\$ or break or tear)).tw.
20. 18 or 19
21. exp vitrectomy/
22. vitrectom\$.tw.
23. PPV\$.tw.
24. or/21-23
25. Endotamponade/
26. sulfur hexafluoride/
27. sulfu\$ hexafluoride\$.tw.
28. hexafluoroethane\$.tw.
29. fluorocarbon/
30. dimeticone/
31. perfluoropropane\$.tw.
32. polydimethylsiloxane\$.tw.
33. perfluoro-n-octane.tw.
34. ((gas or air) adj2 (endotamponade or tamponade)).tw.
35. (SF6 or C2F6 or C3F8).tw.
36. or/25-35
37. 17 and 20 and 24 and 36

QUESTION 6g

Cochrane Library

- #1 MeSH descriptor: [Retinal Perforations] this term only
- #2 macula* NEAR/2 (hole* or break or tear)
- #3 #1 or #2
- #4 phacovitrectom*
- #5 phaco-vitrectom*
- #6 (simultaneous or concomitant) NEAR/1 (phaco* or LOL*)
- #7 #4 or #5 or #6
- #8 #3 and #7

MEDLINE

- 1. comparative study/
- 2. controlled clinical trial/
- 3. control groups/
- 4. cross-over studies/
- 5. single-blind method/
- 6. double-blind method/
- 7. exp randomized controlled trial/
- 8. random allocation/
- 9. meta-analysis/
- 10. network meta-analysis/
- 11. "systematic review"/
- 12. controlled clinical trials as topic/
- 13. randomized controlled trials as topic/
- 14. meta-analysis as topic/
- 15. (compare\$ or control\$ or group or groups or versus or interventional or noninferior\$ or equivalence or random\$).tw.
- 16. or/1-15
- 17. Retinal Perforations/
- 18. (macula\$ adj2 (hole\$ or break or tear)).tw.
- 19. or/17-18
- 20. phacovitrectom\$.tw.
- 21. phaco-vitrectom\$.tw.
- 22. ((simultaneous or concomitant) adj1 (phaco\$ or LOL\$)).tw.
- 23. or/20-22
- 24. 16 and 19 and 23

Embase

- 1. comparative study/
- 2. controlled clinical trial/
- 3. control group/
- 4. crossover procedure/
- 5. single blind procedure/
- 6. double blind procedure/
- 7. exp randomized controlled trial/
- 8. randomization/

9. meta-analysis/
10. network meta-analysis/
11. "systematic review"/
12. "controlled clinical trial (topic)"/
13. "randomized controlled trial (topic)"/
14. "meta analysis (topic)"/
15. "systematic review (topic)"/
16. (compare\$ or control\$ or group or groups or versus or interventional or noninferior\$ or equivalence or random\$).tw.
17. or/1-16
18. Retina Macula Hole/
19. (macula\$ adj2 (hole\$ or break or tear)).tw.
20. 18 or 19
21. phacovitrectomy/
22. phacovitrectom\$.tw.
23. phaco-vitrectom\$.tw.
24. ((simultaneous or concomitant) adj1 (phaco\$ or LOL\$)).tw.
25. or/21-24
26. 17 and 20 and 25

QUESTION 7a-c

MEDLINE

1. Retinal Perforations/
2. (macula\$ adj2 (hole\$ or break or tear)).tw.
3. or/1-2
4. ((anatomical or function\$ or surgery or surgical or hole) adj2 (outcome\$ or success\$ or closure)).tw.
5. (hole\$ adj2 form adj2 factor).tw.
6. (macula\$ adj2 hole adj2 closure adj2 index).tw.
7. (macula\$ adj2 hole adj2 index).tw.
8. (choroidal adj2 vascularity adj2 index).tw.
9. ((diameter or tractional) adj3 (hole adj2 index)).tw.
10. (hole adj2 diameter adj2 ratio\$).tw.
11. Patient Reported Outcome Measures/
12. Patient Satisfaction/
13. (patient\$ adj2 report\$ adj2 outcome\$).tw.
14. PROMS.tw.
15. (patient\$ adj2 (expectation or satisf\$ or dissatisf)).tw.
16. (vision adj1 related adj1 quality adj2 life).tw.
17. (VR-QOL or VRQOL).tw.
18. (VF 14 or VF-14).tw.
19. (VFQ 25 or VFQ-25).tw.
20. (VFQ 39 or VFQ-39).tw.
21. (SF 36 or SF-36).tw.
22. Visual Activities Questionnaire.tw.
23. Visual Disability Assessment.tw.
24. Visual Function Index.tw.

25. visual function\$ 14.tw.
26. "Visual Symptoms and Quality of Life questionnaire".tw.
27. "Visual Function and Quality of Life questionnaire".tw.
28. "Quality of Life and Vision Function Questionnaire".tw.
29. or/4-28
30. Treatment Outcome/
31. Visual Acuity/
32. (visual adj1 acuit\$).tw.
33. or/31-32
34. 30 and 33
35. 29 or 34
36. 3 and 35
37. Assessment of patient-reported outcomes in retinal diseases a systematic review.m_titl.
38. 36 or 37
39. case reports/
40. (case adj2 report\$).tw.
41. or/39-40
42. 38 not 41
43. limit 42 to english language
44. limit 43 to yr="2000 - 2022"
45. limit 44 to (editorial or letter)
46. 44 not 45

Embase

1. retina macula hole/
2. (macula\$ adj2 (hole\$ or break or tear)).tw.
3. or/1-2
4. ((anatomical or function\$ or surgery or surgical or hole) adj2 (outcome\$ or success\$ or closure)).tw.
5. (hole\$ adj2 form adj2 factor).tw.
6. (macula\$ adj2 hole adj2 closure adj2 index).tw.
7. (macula\$ adj2 hole adj2 index).tw.
8. (choroidal adj2 vascularity adj2 index).tw.
9. ((diameter or tractional) adj3 (hole adj2 index)).tw.
10. (hole adj2 diameter adj2 ratio\$).tw.
11. patient-reported outcome/
12. patient satisfaction/
13. (patient\$ adj2 report\$ adj2 outcome\$).tw.
14. PROMS.tw.
15. (patient\$ adj2 (expectation or satisf\$ or dissatisf)).tw.
16. (vision adj1 related adj1 quality adj2 life).tw.
17. (VR-QOL or VRQOL).tw.
18. (VF 14 or VF-14).tw.
19. (VFQ 25 or VFQ-25).tw.
20. (VFQ 39 or VFQ-39).tw.
21. (SF 36 or SF-36).tw.
22. Visual Activities Questionnaire.tw.
23. Visual Disability Assessment.tw.

24. Visual Function Index.tw.
25. visual function\$ 14.tw.
26. "Visual Symptoms and Quality of Life questionnaire".tw.
27. "Visual Function and Quality of Life questionnaire".tw.
28. "Quality of Life and Vision Function Questionnaire".tw.
29. or/4-28
30. treatment outcome/
31. visual acuity/
32. (visual adj1 acuit\$).tw.
33. or/31-32
34. 30 and 33
35. 29 or 34
36. 3 and 35
37. case report/
38. (case adj2 report\$).tw.
39. or/37-38
40. 36 not 39
41. limit 40 to conference abstract status
42. 40 not 41
43. limit 42 to english language
44. limit 43 to yr="2000 - 2022"

QUESTION 8a, 8c

MEDLINE

1. comparative study/
2. controlled clinical trial/
3. control groups/
4. cross-over studies/
5. single-blind method/
6. double-blind method/
7. exp randomized controlled trial/
8. random allocation/
9. meta-analysis/
10. network meta-analysis/
11. "systematic review"/
12. controlled clinical trials as topic/
13. randomized controlled trials as topic/
14. meta-analysis as topic/
15. (compare\$ or control\$ or group or groups or versus or interventional or noninferior\$ or equivalence or random\$).tw.
16. or/1-15
17. Retinal Perforations/
18. (macula\$ adj2 (hole\$ or break or tear)).tw.
19. 17 or 18
20. prone position/
21. (postur\$ or position\$ or prone).tw.

22. facedown.tw.
23. face-down.tw.
24. (face adj2 down).tw.
25. nonsupine.tw.
26. non-supine.tw.
27. (non adj2 supine).tw.
28. seated.tw.
29. or/20-28
30. 16 and 19 and 29
31. case reports/
32. case report\$.tw.
33. 31 or 32
34. 30 not 33
35. limit 34 to english language
36. limit 35 to yr="2000 -Current"

Embase

1. comparative study/
2. controlled clinical trial/
3. control group/
4. crossover procedure/
5. single blind procedure/
6. double blind procedure/
7. exp randomized controlled trial/
8. randomization/
9. meta-analysis/
10. network meta-analysis/
11. "systematic review"/
12. "controlled clinical trial (topic)"/
13. "randomized controlled trial (topic)"/
14. "meta analysis (topic)"/
15. "systematic review (topic)"/
16. (compare\$ or control\$ or group or groups or versus or interventional or noninferior\$ or equivalence or random\$).tw.
17. or/1-16
18. Retina Macula Hole/
19. (macula\$ adj2 (hole\$ or break or tear)).tw.
20. 18 or 19
21. prone position/
22. body position/
23. (postur\$ or position\$ or prone).tw.
24. facedown.tw.
25. face-down.tw.
26. (face adj2 down).tw.
27. nonsupine.tw.
28. non-supine.tw.
29. (non adj2 supine).tw.

30. seated.tw.
31. or/21-30
32. 17 and 20 and 31
33. limit 32 to conference abstract status
34. 32 not 33
35. case report/
36. case report\$.tw.
37. or/35-36
38. 34 not 37
39. limit 38 to english language
40. limit 39 to yr="2000 -Current"

QUESTION 8b

MEDLINE

1. Retinal Perforations/
2. (macula\$ adj2 (hole\$ or break or tear)).tw.
3. or/1-2
4. exp Anti-Bacterial Agents/
5. antibiotic\$.tw.
6. Chloramphenicol/
7. chloramphenicol.tw.
8. Ciprofloxacin/
9. ciprofloxacin.tw.
10. Fusidic Acid/
11. (fusidic adj1 acid).tw.
12. Neomycin/
13. neomycin.tw.
14. Ofloxacin/
15. ofloxacin.tw.
16. or/4-15
17. exp Anti-Inflammatory Agents, Non-Steroidal/
18. nsaid\$.tw.
19. nonsteroidal anti-inflammator\$.tw.
20. non-steroidal anti-inflammator\$.tw.
21. bromfenac.tw.
22. ketorolac.tw.
23. nepafenac.tw.
24. voltarol.tw.
25. or/17-24
26. exp Steroids/
27. dexamethasone.tw.
28. fluoromethalone.tw.
29. (prednisolone or prednisone).tw.
30. steroid\$.tw.
31. or/26-30
32. exp adrenergic beta antagonists/

33. (beta adj2 blocker\$.tw.
34. exp carbonic anhydrase inhibitors/
35. (carbonic adj2 anhydrase adj2 inhibitor\$.tw.
36. acetazolamide.tw.
37. brimonidine.tw.
38. brinzolamide.tw.
39. dorzolamide.tw.
40. iopidine.tw.
41. or/32-40
42. 16 or 25 or 31 or 41
43. 16 and 3
44. 25 and 3
45. 31 and 3
46. 41 and 3
47. 3 and 42
48. exp case reports/
49. (case adj2 report\$.tw.
50. or/48-49
51. 47 not 50
52. limit 51 to english language
53. limit 52 to yr="2000 -Current"

Embase

1. Retina Macula Hole/
2. (macula\$ adj2 (hole\$ or break or tear)).tw.
3. or/1-2
4. exp antibiotic agent/
5. antibiotic\$.tw.
6. Chloramphenicol/
7. chloramphenicol.tw.
8. Ciprofloxacin/
9. ciprofloxacin.tw.
10. Fusidic Acid/
11. (fusidic adj1 acid).tw.
12. Neomycin/
13. neomycin.tw.
14. Ofloxacin/
15. ofloxacin.tw.
16. or/4-15
17. exp nonsteroidal antiinflammatory agent/
18. nsaid\$.tw.
19. nonsteroidal anti-inflammator\$.tw.
20. non-steroidal anti-inflammator\$.tw.
21. bromfenac.tw.
22. ketorolac.tw.
23. nepafenac.tw.
24. voltarol.tw.

25. or/17-24
26. exp steroid/
27. dexamethasone.tw.
28. fluoromethalone.tw.
29. (prednisolone or prednisone).tw.
30. steroid\$.tw.
31. or/26-30
32. exp beta adrenergic receptor blocking agent/
33. (beta adj2 blocker\$.tw.
34. exp carbonate dehydratase inhibitor/
35. (carbonic adj2 anhydrase adj2 inhibitor\$.tw.
36. acetazolamide.tw.
37. brimonidine.tw.
38. brinzolamide.tw.
39. dorzolamide.tw.
40. iopidine.tw.
41. or/32-40
42. 16 or 25 or 31 or 41
43. 3 and 42
44. limit 43 to conference abstract status
45. 43 not 44
46. exp case report/
47. (case adj2 report\$.tw.
48. or/46-47
49. 45 not 48
50. limit 49 to english language
51. limit 50 to yr="2000 -Current"

QUESTION Q9 a,b,c,f and 11 a

MEDLINE

1. Retinal Perforations/
2. (macula\$ adj2 (hole\$ or break or tear)).tw.
3. or/1-2
4. (post-operat\$ adj3 (examin\$ or review\$)).tw.
5. (postoperat\$ adj3 (examin\$ or review\$)).tw.
6. (post-operat\$ adj2 follow adj1 up).tw.
7. (postoperat\$ adj2 follow adj1 up).tw.
8. (surg\$ adj2 follow adj1 up).tw.
9. (treat\$ adj3 review\$).tw.
10. Retreatment/
11. (retreat\$ or re-treat\$.tw.
12. ((repeat\$ or further or additonal or frequen\$) adj3 surg\$.tw.
13. ((repeat\$ or further or additonal or frequen\$) adj3 treat\$.tw.
14. ((repeat\$ or further or additonal or frequen\$) adj3 intervention\$.tw.
15. ((repeat\$ or further or additonal or frequen\$) adj3 therap\$.tw.
16. discharge\$.tw.

17. or/4-16
18. 3 and 17
19. case reports/
20. (case adj2 report\$).tw.
21. or/19-20
22. 18 not 21
23. limit 22 to english language
24. limit 23 to yr="2000 -Current"

Embase

1. Retina Macula Hole/
2. (macula\$ adj2 (hole\$ or break or tear)).tw.
3. or/1-2
4. (post-operat\$ adj3 (examin\$ or review\$)).tw.
5. (postoperat\$ adj3 (examin\$ or review\$)).tw.
6. (post-operat\$ adj2 follow adj1 up).tw.
7. (postoperat\$ adj2 follow adj1 up).tw.
8. (surg\$ adj2 follow adj1 up).tw.
9. (treat\$ adj3 review\$).tw.
10. Retreatment/
11. (retreat\$ or re-treat\$).tw.
12. ((repeat\$ or further or additonal or frequen\$) adj3 surg\$).tw.
13. ((repeat\$ or further or additonal or frequen\$) adj3 surg\$).tw.
14. ((repeat\$ or further or additonal or frequen\$) adj3 treat\$).tw.
15. ((repeat\$ or further or additonal or frequen\$) adj3 intervention\$).tw.
16. ((repeat\$ or further or additonal or frequen\$) adj3 therap\$).tw.
17. or/4-16
18. 3 and 17
19. case report/
20. (case adj2 report\$).tw.
21. or/19-20
22. 18 not 21
23. limit 22 to english language
24. limit 23 to conference abstract status
25. 23 not 24
26. limit 25 to yr="2000 -Current"

QUESTION 9d,e and 11b,c,d

MEDLINE

1. Retinal Perforations/
2. (macula\$ adj2 (hole\$ or break or tear)).tw.
3. or/1-2
4. treatment failure/
5. Recurrence/
6. Reoperation/
7. (fail\$ adj3 clos\$).tw.

8. non-clos\$.tw.
9. (reopen\$ or reoperat\$.tw.
10. (surg\$ adj3 (first or fail\$ or repeat\$ or further or additonal)).tw.
11. (refractory or recurrent or persistent or recalcitrant).tw.
12. or/4-11
13. 3 and 12
14. case reports/
15. (case adj2 report\$.tw.
16. or/14-15
17. 13 not 16
18. limit 17 to english language
19. limit 18 to yr="2000 -Current"
20. limit 19 to (editorial or letter)
21. 19 not 20

Embase

1. Retina Macula Hole/
2. (macula\$ adj2 (hole\$ or break or tear)).tw.
3. or/1-2
4. treatment failure/
5. recurrent disease/
6. reoperation/
7. (fail\$ adj3 clos\$.tw.
8. non-clos\$.tw.
9. (reopen\$ or reoperat\$.tw.
10. (surg\$ adj3 (first or fail\$ or repeat\$ or further or additonal)).tw.
11. (refractory or recurrent or persistent or recalcitrant).tw.
12. or/4-11
13. 3 and 12
14. case report/
15. (case adj2 report\$.tw.
16. or/14-15
17. 13 not 16
18. limit 17 to conference abstract status
19. 17 not 18
20. limit 19 to english language
21. limit 20 to yr="2000 -Current"
22. limit 21 to (editorial or letter)
23. 21 not 22

QUESTION 10a,b

MEDLINE

1. Retinal Perforations/
2. (macula\$ adj2 (hole\$ or break or tear)).tw.
3. or/1-2
4. Postoperative Complications/

5. (postoperative adj2 complication\$).tw.
6. (post-operative adj2 complication\$).tw.
7. (long\$ adj1 term adj2 complication\$).tw.
8. (longterm adj2 complication\$).tw.
9. or/4-8
10. Incidence/ or Prevalence/
11. Epidemiological Monitoring/
12. (incidence or prevalen\$).tw.
13. (proportion or frequen\$).tw.
14. or/10-13
15. 3 and 9 and 14
16. case reports/
17. (case adj2 report\$).tw.
18. or/16-17
19. 15 not 18
20. limit 19 to english language
21. limit 20 to yr="2000 -Current"

Embase

1. Retina Macula Hole/
2. (macula\$ adj2 (hole\$ or break or tear)).tw.
3. or/1-2
4. postoperative complication/
5. (postoperative adj2 complication\$).tw.
6. (post-operative adj2 complication\$).tw.
7. (long\$ adj1 term adj2 complication\$).tw.
8. (longterm adj2 complication\$).tw.
9. or/4-8
10. incidence/
11. prevalence/
12. epidemiological monitoring/
13. (incidence or prevalen\$).tw.
14. (proportion or frequen\$).tw.
15. or/10-14
16. 3 and 9 and 15
17. case report/
18. (case adj2 report\$).tw.
19. or/17-18
20. 16 not 19
21. limit 20 to conference abstract status
22. 20 not 21
23. limit 22 to english language
24. limit 23 to yr="2000 -Current"

References

1. Pasu S, Bell L, Zenasni Z, Lanz D, Simmonds IA, Thompson A, Yorston D, Laidlaw DAH, Bunce C, Hooper R, Bainbridge JWB; Positioning In Macular Hole Surgery (PIMS) Study Group. Facedown Positioning Following Surgery for Large Full-Thickness Macular Hole: A Multicenter Randomized Clinical Trial. *JAMA Ophthalmol.* 2020 Jul 1;138(7):725-730.
2. Lindtjørn B, Krohn J, Haugstad M, Stene-Johansen I, Austeng D, Basit S, Fossen K, Varhaug P, Kvaløy JT, Forsaa VA. Air versus Sulfur Hexafluoride Gas Tamponade for Small and Medium-Sized Macular Holes: A Randomized Noninferiority Trial. *Ophthalmol Retina.* 2022 Sep;6(9):828-834.
3. Wada, I., Yoshida, S., Kobayashi, Y., Zhou, Y., Ishikawa, K., Nakao, S., Hisatomi, T., Ikeda, Y., Ishibashi, T., & Sonoda, K. H. (2017). Quantifying metamorphopsia with M-CHARTS in patients with idiopathic macular hole. *Clinical Ophthalmology*, 11, 1719–1726.
4. Patel PJ, Steel DH, Hirneiß C, Brazier J, Aly A, Lescrauwaet B; MeMo Study Group. Patient-reported prevalence of metamorphopsia and predictors of vision-related quality of life in vitreomacular traction: a prospective, multi-centre study. *Eye (Lond).* 2019 Mar;33(3):435-444.
5. Darian-Smith E, Howie AR, Allen PL, Vote BJ. Tasmanian macular hole study: whole population-based incidence of full thickness macular hole. *Clin Exp Ophthalmol.* 2016;44(9):812-6.
6. Forsaa VA, Lindtjørn B, Kvaløy JT, Frøystein T, Krohn J. Epidemiology and morphology of full-thickness macular holes. *Acta Ophthalmol.* 2018;96(4):397-404.
7. Menzler J, Neubauer AS, Haritoglou C, Jackson TL. Incidence and prevalence of vitreomacular traction with and without macular hole in Germany. *Clin Ophthalmol.* 2019;13:177-88.
8. Cho SC, Park SJ, Byun SJ, Woo SJ, Park KH. Five-year nationwide incidence of macular hole requiring surgery in Korea. *Br J Ophthalmol.* 2019;103(11):1619-23.
9. Ali FS, Stein JD, Blachley TS, Ackley S, Stewart JM. Incidence of and Risk Factors for Developing Idiopathic Macular Hole Among a Diverse Group of Patients Throughout the United States. *JAMA Ophthalmol.* 2017;135(4):299-305.
10. Rahmani B, Tielsch JM, Katz J, Gottsch J, Quigley H, Javitt J, et al. The cause-specific prevalence of visual impairment in an urban population. The Baltimore Eye Survey. *Ophthalmology.* 1996;103(11):1721-6.
11. Wang S, Xu L, Jonas JB. Prevalence of full-thickness macular holes in urban and rural adult Chinese: the Beijing Eye Study. *Am J Ophthalmol.* 2006;141(3):589-91.
12. Sen P, Bhargava A, Vijaya L, George R. Prevalence of idiopathic macular hole in adult rural and urban south Indian population. *Clin Exp Ophthalmol.* 2008;36(3):257-60.
13. Mitchell P, Smith W, Chey T, Wang JJ, Chang A. Prevalence and associations of epiretinal membranes. The Blue Mountains Eye Study, Australia. *Ophthalmology.* 1997;104(6):1033-40.
14. Meuer SM, Myers CE, Klein BE, Swift MK, Huang Y, Gangaputra S, et al. The epidemiology of vitreoretinal interface abnormalities as detected by spectral-domain optical coherence tomography: the beaver dam eye study. *Ophthalmology.* 2015;122(4):787-95.
15. Nirmalan PK, Katz J, Robin AL, Tielsch JM, Namperumalsamy P, Kim R, et al. Prevalence of vitreoretinal disorders in a rural population of southern India: the Aravind Comprehensive Eye Study. *Arch Ophthalmol.* 2004;122(4):581-6.
16. Darian-Smith E, Howie AR, Allen PL, Vote BJ. Tasmanian macular hole study: whole population-based incidence of full thickness macular hole. *Clin Exp Ophthalmol.* 2016;44(9):812-6.
17. McCannel CA, Ensminger JL, Diehl NN, Hodge DN. Population-based incidence of macular holes. *Ophthalmology.* 2009;116(7):1366-9.
18. Parvus MN, Louis AM, Trejo Corona S, Wong TP, Major JC, Patel SB, et al. Impact of Race and Ethnicity on Presentation and Surgical Outcomes of Idiopathic Macular Holes. *J Pers Med.* 2022;12(9).
19. Valentim CCS, Iyer AI, Xu C, Muste JC, Li A, Singh RP. Influence of Race, Ethnicity, and Socioeconomic Factors in Idiopathic Macular Hole Presentation and Surgical Outcomes. *Ophthalmic Surg Lasers Imaging Retina.* 2022;53(6):333-44.

20. Takahashi A, Yoshida A, Nagaoka T, Kagokawa H, Kato Y, Takamiya A, et al. Macular hole formation in fellow eyes with a perifoveal posterior vitreous detachment of patients with a unilateral macular hole. *Am J Ophthalmol.* 2011;151(6):981-9.e4
21. Lewis ML, Cohen SM, Smiddy WE, Gass JD. Bilaterality of idiopathic macular holes. *Graefes Arch Clin Exp Ophthalmol.* 1996;234(4):241-5.
22. Murphy DC, Melville HJR, George G, Grinton M, Chen Y, Rees J, et al. The Association between Foveal Floor Measurements and Macular Hole Size. *Ophthalmol Retina.* 2021;5(7):680-6.
23. Ali FS, Stein JD, Blachley TS, Ackley S, Stewart JM. Incidence of and Risk Factors for Developing Idiopathic Macular Hole Among a Diverse Group of Patients Throughout the United States. *JAMA Ophthalmol.* 2017;135(4):299-305.
24. Foos RY, Wheeler NC. Vitreoretinal juncture. Synchysis senilis and posterior vitreous detachment. *Ophthalmology.* 1982;89(12):1502-12.
25. Yonemoto J, Ideta H, Sasaki K, Tanaka S, Hirose A, Oka C. The age of onset of posterior vitreous detachment. *Graefes Arch Clin Exp Ophthalmol.* 1994;232(2):67-70.
26. Chuo JY, Lee TY, Hollands H, Morris AH, Reyes RC, Rossiter JD, et al. Risk factors for posterior vitreous detachment: a case-control study. *Am J Ophthalmol.* 2006;142(6):931-7.
27. Huang J, Liu X, Wu Z, Sadda S. Comparison of full-thickness traumatic macular holes and idiopathic macular holes by optical coherence tomography. *Graefes Arch Clin Exp Ophthalmol.* 2010;248(8):1071-5.
28. Liu W, Grzybowski A. Current Management of Traumatic Macular Holes. *J Ophthalmol.* 2017;2017:1748135.
29. Chandra A, Lai M, Mitry D, Banerjee PJ, Flayeh H, Negretti G, et al. Ethnic variation in primary idiopathic macular hole surgery. *Eye.* 2017;31(5):708-12.
30. Papavasileiou E, Vasalaki M, Velissaris S, Garnavou-Xirou C, Zygoura V, Theodorou O, et al. Characteristics, socioeconomic status and ethnic variations of primary idiopathic macular hole repair in vitreoretinal centers in the United Kingdom. *Hell J Nucl Med.* 2017;20 Suppl:160
31. Gupta B, Neffendorf JE, Wong R, Laidlaw DAH, Williamson TH. Ethnic Variation in Vitreoretinal Surgery: Differences in Clinical Presentation and Outcome. *European Journal of Ophthalmology.* 2017;27(3):367-71.
32. Wagner-Schuman M, Dubis AM, Nordgren RN, Lei Y, Odell D, Chiao H, et al. Race- and sex-related differences in retinal thickness and foveal pit morphology. *Invest Ophthalmol Vis Sci.* 2011;52(1):625-34.
33. Zouache MA, Silvestri G, Amoaku WM, Silvestri V, Hubbard WC, Pappas C, et al. Comparison of the Morphology of the Foveal Pit Between African and Caucasian Populations. *Transl Vis Sci Technol.* 2020;9(5):24.
34. Chhablani J, Kumar K, Ali TR, Narayanan R. Spectral-domain optical coherence tomography features in fellow eyes of patients with idiopathic macular hole. *Eur J Ophthalmol.* 2014;24(3):382-6.
35. Lindtjørn B, Krohn J, Forsaa VA. Optical coherence tomography features and risk of macular hole formation in the fellow eye. *BMC Ophthalmol.* 2021;21(1):351.
36. Ezra E. Idiopathic full thickness macular hole: natural history and pathogenesis. *Br J Ophthalmol.* 2001;85(1):102-8.
37. Trempe CL, Weiter JJ, Furukawa H. Fellow eyes in cases of macular hole. Biomicroscopic study of the vitreous. *Arch Ophthalmol.* 1986;104(1):93-5.
38. Aaberg TM, Blair CJ, Gass JD. Macular holes. *Am J Ophthalmol.* 1970;69(4):555-62.
39. Bronstein MA, Trempe CL, Freeman HM. Fellow eyes of eyes with macular holes. *Am J Ophthalmol.* 1981;92(6):757-61.
40. Choi JH, Kim KT, Kang SW, Bae K, Lee SE, Kim AY. Development Of Idiopathic Macular Hole In Fellow Eyes: Spectral Domain Optical Coherence Tomography Features. *Retina.* 2020;40(4):765-72.
41. Niwa H, Terasaki H, Ito Y, Miyake Y. Macular hole development in fellow eyes of patients with unilateral macular hole. *Am J Ophthalmol.* 2005;140(3):370-5.
42. Furashova O, Matthé E. Foveal crack sign as a predictive biomarker for development of macular hole in fellow eyes of patients with full-thickness macular holes. *Sci Rep.* 2020;10(1):19932.

43. Chew EY, Sperduto RD, Hiller R, Nowroozi L, Seigel D, Yanuzzi LA, et al. Clinical course of macular holes: the Eye Disease Case-Control Study. *Arch Ophthalmol*. 1999;117(2):242-6.
44. Chan A, Duker JS, Schuman JS, Fujimoto JG. Stage 0 macular holes: observations by optical coherence tomography. *Ophthalmology*. 2004;111(11):2027-32.
45. Staropoli PC, Moolani HV, Elhusseiny AM, Flynn HW, Jr., Smiddy WE. Rates of Fellow Eye Macular Hole Development During Long Term Follow-Up. *Clin Ophthalmol*. 2023;17:47-52
46. Ezra E, Wells JA, Gray RH, Kinsella FM, Orr GM, Grego J, et al. Incidence of idiopathic full-thickness macular holes in fellow eyes. A 5-year prospective natural history study. *Ophthalmology*. 1998;105(2):353-9
47. Johnson RN, Gass JDM. Idiopathic Macular Holes: Observations, Stages of Formation, and Implications for Surgical Intervention. *Ophthalmology*. 1988;95(7):917-24.
48. Morescalchi F, Costagliola C, Gambicorti E, Duse S, Romano MR, Semeraro F. Controversies over the role of internal limiting membrane peeling during vitrectomy in macular hole surgery. *Survey of Ophthalmology*. 2017;62(1):58-69.
49. Bikbova G, Oshitari T, Baba T, Yamamoto S, Mori K. Pathogenesis and Management of Macular Hole: Review of Current Advances. *J Ophthalmol*. 2019;2019:3467381.
50. Johnson MW. Posterior vitreous detachment: evolution and complications of its early stages. *Am J Ophthalmol*. 2010;149(3):371-82.e1.
51. Johnson MW. Perifoveal vitreous detachment and its macular complications. *Trans Am Ophthalmol Soc*. 2005;103:537-67
52. Johnson MW, Van Newkirk MR, Meyer KA. Perifoveal vitreous detachment is the primary pathogenic event in idiopathic macular hole formation. *Arch Ophthalmol*. 2001;119(2):215-22
53. Haouchine B, Massin P, Gaudric A. Foveal pseudocyst as the first step in macular hole formation: a prospective study by optical coherence tomography. *Ophthalmology*. 2001;108(1):15-22.
54. Gaudric A, Haouchine B, Massin P, Paques M, Blain P, Erginay A. Macular hole formation: new data provided by optical coherence tomography. *Arch Ophthalmol*. 1999;117(6):744-51
55. Cour M, Friis J. Macular holes: classification, epidemiology, natural history and treatment. *Acta Ophthalmol Scand*. 2002;80(6):579-87
56. Mori K, Gehlbach PL, Kishi S. Posterior Vitreous Mobility Delineated by Tracking of Optical Coherence Tomography Images in Eyes With Idiopathic Macular Holes. *American Journal of Ophthalmology*. 2015;159(6):1132-41.e1
57. Chung H, Byeon SH. New insights into the pathoanatomy of macular holes based on features of optical coherence tomography. *Surv Ophthalmol*. 2017;62(4):506-21.
58. Smiddy WE, Flynn HW. Pathogenesis of macular holes and therapeutic implications. *American Journal of Ophthalmology*. 2004;137(3):525-37.
59. Schubert HD, Kuang K, Kang F, Head MW, Fischbarg J. Macular holes: migratory gaps and vitreous as obstacles to glial closure. *Graefes Arch Clin Exp Ophthalmol*. 1997;235(8):523-9.
60. Gentile RC, Landa G, Pons ME, Elliott D, Rosen RB. Macular hole formation, progression, and surgical repair: case series of serial optical coherence tomography and time lapse morphing video study. *BMC Ophthalmol*. 2010;10:24.
61. Woon WH, Greig D, Savage MD, Wilson MC, Grant CA, Mokete B, et al. Movement of the inner retina complex during the development of primary full-thickness macular holes: implications for hypotheses of pathogenesis. *Graefes Arch Clin Exp Ophthalmol*. 2015;253(12):2103-9
62. Tornambe PE. Macular hole genesis: the hydration theory. *Retina*. 2003;23(3):421-4
63. Risk factors for idiopathic macular holes. The Eye Disease Case-Control Study Group. *Am J Ophthalmol*. 1994;118(6):754-61
64. Evans JR, Schwartz SD, McHugh JD, Thamby-Rajah Y, Hodgson SA, Wormald RP, et al. Systemic risk factors for idiopathic macular holes: a case-control study. *Eye (Lond)*. 1998;12 (Pt 2):256-9
65. Singh AJ, Muqit MM, Woon WH. Is axial length a risk factor for idiopathic macular hole formation? *Int Ophthalmol*. 2012;32(4):393-6

66. Kobayashi H, Kobayashi K, Okinami S. Macular hole and myopic refraction. *Br J Ophthalmol.* 2002;86(11):1269-73.
67. Barak Y, Ihnen MA, Schaal S. Spectral domain optical coherence tomography in the diagnosis and management of vitreoretinal interface pathologies. *J Ophthalmol.* 2012;2012:876472.
68. Philippakis E, Astroz P, Tadayoni R, Gaudric A. Incidence of Macular Holes in the Fellow Eye without Vitreomacular Detachment at Baseline. *Ophthalmologica.* 2018;240(3):135-42.
69. Michalewska Z, Michalewski J, Sikorski BL, Kałuzny JJ, Wojtkowski M, Adelman RA, et al. A study of macular hole formation by serial spectral optical coherence tomography. *Clin Exp Ophthalmol.* 2009;37(4):373-83.
70. Otsuji F, Uemura A, Nakano T, Sakamoto T. Long-term observation of the vitreomacular relationship in normal fellow eyes of patients with unilateral idiopathic macular holes. *Ophthalmologica.* 2014;232(4):188-93
71. Spiritus A, Dralands L, Stalmans P, Stalmans I, Spileers W. OCT study of fellow eyes of macular holes. *Bull Soc Belge Ophtalmol.* 2000;275:81-4
72. Scharf JM, Hilely A, Preti RC, Grondin C, Chehaibou I, Greaves G, et al. Hyperreflective Stress Lines and Macular Holes. *Investigative Ophthalmology & Visual Science.* 2020;61(4):50-
73. Dalan D, Jaisankar D, Mani K, Madhu A, Ratra D. A multifocal electroretinography study to evaluate risk of developing macular hole in the fellow eye of patients suffering with unilateral macular hole. *Ther Adv Ophthalmol.* 2020;12:2515841420908697.
74. Tuzson R, Varsanyi B, Vince Nagy B, Lesch B, Vámos R, Németh J, et al. Role of multifocal electroretinography in the diagnosis of idiopathic macular hole. *Invest Ophthalmol Vis Sci.* 2010;51(3):1666-70
75. Aljohani S, Alshehri A, Al Teisan A, et al. Analysis of complications for epiretinal Membrane and Macular Hole Surgery performed by vitreoretinal fellows and consultants. *Clin Ophthalmol* 2021; 15: 1905-1911
76. Jenisch TM, Zeman F, Koller M et al. Macular hole surgery: an analysis of risk factors for the anatomical and functional outcomes with a special emphasis on the experience of the surgeon. *Clin Ophthalmol* 2017; 11: 1127-1134
77. Wang Y, Zhao x, Zhang W et al. Three-dimensional head-up display versus standard operating microscope for vitrectomy surgery. *Retina* 2022; 42: 1152-1160
78. Kantor P, Matonti F, Varene F et al Use of the Heads-up NGENUITY visualisation system for vitreoretinal surgery: a retrospective evaluation of outcomes in a French tertiary centre. *Nature Portfolio* 2021; 11: 10031
79. Yee P, Sevgi DD, Abraham J, Srivastava SK, Le T, Uchida A, Figueiredo N, Rachitskaya AV, Sharma S, Reese J, Ehlers JP. iOCT-assisted macular hole surgery: outcomes and utility from the DISCOVER study. *Br J Ophthalmol.* 2021 Mar;105(3):403-409
80. Gass JD. Reappraisal of biomicroscopic classification of stages of development of a macular hole. *Am J Ophthalmol.* 1995;119(6):752-9. Doi: 10.1016/s0002-9394(14)72781-3.
81. Duker JS, Kaiser PK, Binder S, de Smet MD, Gaudric A, Reichel E, Sadda SR, Sebag J, Spaide RF, Stalmans P. The International Vitreomacular Traction Study Group classification of vitreomacular adhesion, traction, and macular hole. *Ophthalmology.* 2013;120(12):2611-2619
82. Benson SE, Schlottmann PG, Bunce C, Charteris DG. Comparison of macular hole size measured by optical coherence tomography, digital photography, and clinical examination. *Eye (Lond).* 2008;22(1):87-90.
83. Antonopoulou PG, Baumann C, Jalil A, Dhawahir-Scala F, Muñoz-Sanz N, Lu VHJ, Park D, Patton N. How Big is the Hole? Measuring Intra- and Inter-Individual Agreement in Macular Hole Size Measurements. *Curr Eye Res.* 2020 Aug;45(8):1000-1004
84. Ip MS, Baker BJ, Duker JS, Reichel E, Baumaal CR, Gangnon R, Puliafito CA. Anatomical outcomes of surgery for idiopathic macular hole as determined by optical coherence tomography. *Arch Ophthalmol.* 2002;120(1):29-35
85. Ullrich S, Haritoglou C, Gass C, Schaumberger M, Ulbig MW, Kampik A. Macular hole size as a prognostic factor in macular hole surgery. *British Journal of Ophthalmology* 2002;86:390-393

86. Steel DH, Donachie PHJ, Aylward GW, Laidlaw DA, Williamson TH, Yorston D; BEAVRS Macular hole outcome group. Factors affecting anatomical and visual outcome after macular hole surgery: findings from a large prospective UK cohort. *Eye (Lond)*. 2021;35(1):316-325
87. Conway MP, Forristal MT, Treacy MP, Duignan ES. Investigating the Role of Optometrists in Teleophthalmology and the Implications of Increasing Access to Advanced Imaging Techniques and Digital Referral: A Systematic Search and Review. *Telemed J E Health*. 2021;27(9):974-981
88. College of Optometrists. Clinical Management Guidelines: Vitreomacular Traction and Macular Hole. 2023. URL: <https://www.college-optometrists.org/clinical-guidance/clinical-management-guidelines/vitreomacular-traction-and-macular-hole>
89. Nicolosi, C.; Vicini, G.; Bacherini, D.; Giattini, D.; Lombardi, N.; Esposito, C.; Rizzo, S.; Giansanti, F. Non-Invasive Retinal Imaging Modalities for the Identification of Prognostic Factors in Vitreoretinal Surgery for Full-Thickness Macular Holes. *Diagnostics* 2023, 13, 589
90. De Bustros S, The Vitrectomy for Prevention of Macular Hole Study Group. Vitrectomy for the prevention of macular holes: results of a randomized clinical trial. *Ophthalmology* 1994;101:1055-60
91. Parravano M, Giansanti F, Eandi CM, Yap YC, Rizzo S, Virgili G. Vitrectomy for idiopathic macular hole. *Cochrane Database Syst Rev*. 2015;2015(5):CD009080
92. Liang X, Liu W. Characteristics and Risk Factors for Spontaneous Closure of Idiopathic Full-Thickness Macular Hole. *J Ophthalmol*. 2019 Mar 13;2019:4793764
93. Murphy DC, Al-Zubaidy M, Lois N, Scott N, Steel DH. The effect of macular hole duration on surgical outcomes: an individual participant data study of randomized controlled trials. *Ophthalmology*. 2023;130:152-63.
94. Raimondi R, Ghazal D, Steel DH. Reducing time to surgery in patients affected by idiopathic full thickness macular holes. *Eye (Lond)*. 2023 Nov;37(16):3509-3510
95. Royal College of Ophthalmologists. Vitreoretinal (VR) service standards 2021. URL: <https://www.rcophth.ac.uk/resources-listing/quality-standards-for-vitreoretinal-services> *accessed 20.11.23
96. British and Eire Association of Vitreoretinal Surgeons (BEAVRS). Requirements for a Consultant Vitreoretinal Surgeon. 2023. URL: <https://beavrs.org/requirements-for-a-consultant-vitreoretinal-surgeon> (accessed 20.11.23)
97. Hubschman JP, Govetto A, Spaide RF, Schumann R, Steel D, Figueroa MS, et al. Optical coherence tomography-based consensus definition for lamellar macular hole. *Br J Ophthalmol*. 2020;104(12):1741-7
98. Gass JD. Idiopathic senile macular hole. Its early stages and pathogenesis. *Arch Ophthalmol*. 1988;106(5):629-39
99. Benyamini S, Loewenstein A, Moisseiev E. Evaluation Of Accuracy And Uniformity Of The Nomenclature Of Vitreoretinal Interface Disorders. *Retina*. 2020;40(7):1272-8
100. Altaweel M, Ip M. Macular hole: improved understanding of pathogenesis, staging, and management based on optical coherence tomography. *Semin Ophthalmol*. 2003;18(2):58-66.
101. Madi HA, Masri I, Steel DH. Optimal management of idiopathic macular holes. *Clin Ophthalmol*. 2016;10:97-116
102. Ruiz-Moreno JM, Staicu C, Piñero DP, Montero J, Lugo F, Amat P. Optical coherence tomography predictive factors for macular hole surgery outcome. *Br J Ophthalmol*. 2008;92(5):640-4.
103. Wakely L, Rahman R, Stephenson J. A comparison of several methods of macular hole measurement using optical coherence tomography, and their value in predicting anatomical and visual outcomes. *Br J Ophthalmol*. 2012;96(7):1003-7
104. Murphy DC, Nasrullo AV, Lendrem C, Graziado S, Alberti M, la Cour M, Obara B, Steel DHW. Predicting Postoperative Vision for Macular Hole with Automated Image Analysis. *Ophthalmol Retina*. 2020 Dec;4(12):1211-1213.
105. Ryan EH, Jr., Gilbert HD. Results of surgical treatment of recent-onset full-thickness idiopathic macular holes. *Arch Ophthalmol*. 1994;112(12):1545-53
106. Freeman WR, Azen SP, Kim JW, el-Haig W, Mishell DR, 3rd, Bailey I. Vitrectomy for the treatment of full-thickness stage 3 or 4 macular holes. Results of a multicentered randomized clinical trial. The Vitrectomy for Treatment of Macular Hole Study Group. *Arch Ophthalmol*. 1997;115(1):11-21

107. Ruby AJ, Williams DF, Grand MG, Thomas MA, Meredith TA, Boniuk I, et al. Pars plana vitrectomy for treatment of stage 2 macular holes. *Arch Ophthalmol*. 1994;112(3):359-64.
108. Williamson TH, Lee E. Idiopathic macular hole: analysis of visual outcomes and the use of indocyanine green or brilliant blue for internal limiting membrane peel. *Graefes Archive for Clinical and Experimental Ophthalmology*. 2014;252(3):395-400.
109. Salter AB, Folgar FA, Weissbrot J, Wald KJ. Macular hole surgery prognostic success rates based on macular hole size. *Ophthalmic Surg Lasers Imaging*. 2012;43(3):184-9
110. Gupta B, Laidlaw DA, Williamson TH, Shah SP, Wong R, Wren S. Predicting visual success in macular hole surgery. *Br J Ophthalmol*. 2009;93(11):1488-91.
111. Ch'ng SW, Patton N, Ahmed M, Ivanova T, Baumann C, Charles S, et al. The Manchester Large Macular Hole Study: Is it Time to Reclassify Large Macular Holes? *Am J Ophthalmol*. 2018;195:36-42
112. Steel DH, Donachie PHJ, Laidlaw DA, Williamson TH, Yorston D. Response to 'Comment on: Factors affecting anatomical and visual outcome after macular hole surgery: findings from a large prospective UK cohort'. *Eye (Lond)*. 2021;35(5):1513-4.
113. Rezende FA, Ferreira BG, Rampakakis E, Steel DH, Koss MJ, Nawrocka ZA, et al. Surgical classification for large macular hole: based on different surgical techniques results: the CLOSE study group. *International Journal of Retina and Vitreous*. 2023;9(1):4.
114. Ezra E, Gregor ZJ. Surgery for idiopathic full-thickness macular hole: two-year results of a randomized clinical trial comparing natural history, vitrectomy, and vitrectomy plus autologous serum: Morfields Macular Hole Study Group RAeport no. 1. *Arch Ophthalmol*. 2004;122(2):224-36.
115. Stalmans P, Benz MS, Gandorfer A, Kampik A, Girach A, Pakola S, et al. Enzymatic vitreolysis with ocriplasmin for vitreomacular traction and macular holes. *N Engl J Med*. 2012;367(7):606-15.
116. Canamary A, Jr., Rios L, Pinheiro F, Capelanes N, Regatieri C. Spontaneous closure of idiopathic full-thickness macular hole after release of vitreomacular traction observed on spectral-domain optical coherence tomography. *Saudi J Ophthalmol*. Oct-Dec 2021;35(4):362-364. doi:10.4103/1319-4534.347310
117. Gonzalez-Cortes JH, Toledo-Negrete JJ, Bages-Rousselon Y, de Alba-Castilla MA, Mohamed-Hamsho J. Spontaneous Closure of Simultaneous Idiopathic Macular Holes Documented by Spectral-Domain Optical Coherence Tomography. *Retin Cases Brief Rep*. Jan 1 2021;15(1):27-30
118. Jackson TL, Regillo CD, Girach A, Dugel PU, Group M-TS. Baseline Predictors of Vitreomacular Adhesion/Traction Resolution Following an Intravitreal Injection of Ocriplasmin. *Ophthalmic surgery, lasers & imaging retina*. Aug 1 2016;47(8):716-23
119. Haller JA, Stalmans P, Benz MS, et al. Efficacy of intravitreal ocriplasmin for treatment of vitreomacular adhesion: subgroup analyses from two randomized trials. *Ophthalmology*. Jan 2015;122(1):117-22
120. Dugel PU, Tolentino M, Feiner L, Kozma P, Leroy A. Results of the 2-Year Ocriplasmin for Treatment for Symptomatic Vitreomacular Adhesion Including Macular Hole (OASIS) Randomized Trial. *Ophthalmology*. Oct 2016;123(10):2232-47.
121. Kim JW, Freeman WR, Azen SP, el-Haig W, Klein DJ, Bailey IL. Prospective randomized trial of vitrectomy or observation for stage 2 macular holes. *Vitrectomy for Macular Hole Study Group*. *American journal of ophthalmology*. Jun 1996;121(6):605-14
122. Kim JW, Freeman WR, el-Haig W, Maguire AM, Arevalo JF, Azen SP. Baseline characteristics, natural history, and risk factors to progression in eyes with stage 2 macular holes. Results from a prospective randomized clinical trial. *Vitrectomy for Macular Hole Study Group*. *Ophthalmology*. Dec 1995;102(12):1818-28; discussion 1828-9
123. Guyer DR, de Bustros S, Diener-West M, Fine SL. Observations on patients with idiopathic macular holes and cysts. *Archives of ophthalmology*. Sep 1992;110(9):1264-8.
124. Chew EY, Sperduto RD, Hiller R, et al. Clinical course of macular holes: the Eye Disease Case-Control Study. *Archives of ophthalmology*. Feb 1999;117(2):242-6.
125. Yuzawa M, Watanabe A, Takahashi Y, Matsui M. Observation of idiopathic full-thickness macular holes. Follow-up observation. *Archives of ophthalmology*. Aug 1994;112(8):1051-6

126. Dugel PU, Tolentino M, Feiner L, Kozma P, Leroy A. Results of the 2-Year Ocriplasmin for Treatment for Symptomatic Vitreomacular Adhesion Including Macular Hole (OASIS) Randomized Trial. *Ophthalmology*. Oct 2016;123(10):2232-47
127. Jackson TL, Donachie PH, Sparrow JM, Johnston RL. United Kingdom National Ophthalmology Database study of vitreoretinal surgery: report 2, macular hole. *Ophthalmology*. Mar 2013;120(3):629-34.
128. JETREA: Summary of Product Characteristics. Datapharm Ltd. Accessed 29/2/23, 2023. <https://www.medicines.org.uk/emc/product/9416>
129. National Institute for Health and Care Excellence (NICE). Ocriplasmin for treating vitreomacular traction: technology appraisal guidance [TA297]. Accessed 29/2/23, 2023. <https://www.nice.org.uk/guidance/ta297/chapter/1-Guidance>
130. Neffendorf JE, Kirthi V, Pringle E, Jackson TL. Ocriplasmin for symptomatic vitreomacular adhesion. *Cochrane database of systematic reviews (Online)*. Oct 17 2017;10:CD011874. doi:10.1002/14651858.CD011874.pub2
131. Stalmans P, Delaey C, de Smet MD, van Dijkman E, Pakola S. Intravitreal injection of microplasmin for treatment of vitreomacular adhesion: results of a prospective, randomized, sham-controlled phase II trial (the MIVI-IIT trial). *Retina*. 2010 Jul-Aug;30(7):1122-7.
132. Jackson TL, Haller J, Blot KH, Duchateau L, Lescrauwaet B. Ocriplasmin for treatment of vitreomacular traction and macular hole: A systematic literature review and individual participant data meta-analysis of randomized, controlled, double-masked trials. *Survey of ophthalmology*. Sep 2 2021
133. Bennison C, Stephens S, Lescrauwaet B, Van Hout B, Jackson TL. Cost-effectiveness of ocriplasmin for the treatment of vitreomacular traction and macular hole. *J Mark Access Health Policy*. 2016
134. Chang JS, Smiddy WE. Cost evaluation of surgical and pharmaceutical options in treatment for vitreomacular adhesions and macular holes. *Ophthalmology*. Sep 2014;121(9):1720-6
135. Kim JE. Safety and complications of ocriplasmin: Ocriplasmin, ocriplasmin; oh, how safe art thou? *JAMA Ophthalmol*. 2014;132(4):379-380
136. Fahim AT, Khan NW, Johnson MW. Acute panretinal structural and functional abnormalities after intravitreal ocriplasmin injection. *JAMA Ophthalmol*. Apr 1 2014;132(4):484-6.
137. reund KB, Shah SA, Shah VP. Correlation of transient vision loss with outer retinal disruption following intravitreal ocriplasmin. *Eye*. Jun 2013;27(6):773-4
138. Hager A, Seibel I, Riechart A, Rehak M, Jousen AM. Does ocriplasmin affect the RPE-photoreceptor adhesion in macular holes? *The British journal of ophthalmology*. May 2015;99(5):635-8.
139. Tibbetts MD, Reichel E, Witkin AJ. Vision loss after intravitreal ocriplasmin: correlation of spectral-domain optical coherence tomography and electroretinography. *JAMA Ophthalmol*. Apr 1 2014;132(4):487-90
140. Thanos A, Hernandez-Siman J, Marra KV, Arroyo JG. Reversible vision loss and outer retinal abnormalities after intravitreal ocriplasmin injection. *Retin Cases Brief Rep*. Fall 2014;8(4):330-2
141. Gomez-Ulla F, Bande MF, Abraldes M. Acute loss of vision after an intravitreal injection ocriplasmin: a functional evolutionary study for 1-year follow-up. *Documenta ophthalmologica Advances in ophthalmology*. Dec 2015;131(3):231-5
142. Quezada Ruiz C, Pieramici DJ, Nasir M, Rabena M, Avery RL. Severe acute vision loss, dyschromatopsia, and changes in the ellipsoid zone on sd-oct associated with intravitreal ocriplasmin injection. *Retin Cases Brief Rep*. Spring 2015;9(2):145-8.
143. Reiss B, Smithen L, Mansour S. Acute vision loss after ocriplasmin use. *Retin Cases Brief Rep*. Spring 2015;9(2):168-9
144. Haynes RJ, Yorston D, Laidlaw DA, Keller J, Steel DH. Real world outcomes of ocriplasmin use by members of the British and Eire Association of Vitreoretinal Surgeons. *Eye*. Jan 2017;31(1):107-112
145. Fazel F, Rezaeian-Ramsheh A, Fazel M, Ahmadi H. Closure of idiopathic full-thickness macular hole after intravitreal C3F8 injection without vitreomacular traction release: A case report and review of literature. *Retin Cases Brief Rep*. Aug 19 2022.

146. Chan CK, Mein CE, Crosson JN. Pneumatic Vitreolysis for Management of Symptomatic Focal Vitreomacular Traction. *J Ophthalmic Vis Res.* Oct-Dec 2017;12(4):419-423
147. Chan CK, Wessels IF, Friedrichsen EJ. Treatment of idiopathic macular holes by induced posterior vitreous detachment. *Ophthalmology.* May 1995;102(5):757-67.
148. Costa RA, Cardillo JA, Morales PH, Jorge R, Uno F, Farah ME. Optical coherence tomography evaluation of idiopathic macular hole treatment by gas-assisted posterior vitreous detachment. *American journal of ophthalmology.* Aug 2001;132(2):264-6
149. Jorge R, Costa RA, Cardillo JA, Uno F, Bonomo PP, Farah ME. Optical coherence tomography evaluation of idiopathic macular hole treatment by gas-assisted posterior vitreous detachment. *American journal of ophthalmology.* Nov 2006;142(5):869-71
150. Quiroz-Reyes MA, Quiroz-Gonzalez EA, Quiroz-Gonzalez MA, Lima-Gomez V. Pneumatic vitreolysis versus vitrectomy for the treatment of vitreomacular traction syndrome and macular holes: complication analysis and systematic review with meta-analysis of functional outcomes. *Int J Retina Vitreous.* May 22 2023;9(1):33.
151. Čokl N, Globočnik Petrovič M. Intravitreal Injection of Perfluoropropane is More Efficacious than Sulfur Hexafluoride In Releasing Vitreomacular Traction. *Acta Clin Croat.* 2018 Jun;57(2):327-334
152. Yu G, Duguay J, Marra KV, et al. Efficacy And Safety Of Treatment Options For Vitreomacular Traction: A Case Series and Meta-Analysis. *Retina.* Jul 2016;36(7):1260-70.
153. Fallico M, Jackson TL, Chronopoulos A, et al. Factors predicting normal visual acuity following anatomically successful macular hole surgery. *Acta ophthalmologica.* May 2021;99(3):e324-e329
154. Madi HA, Dinah C, Rees J, Steel DH. The Case Mix of Patients Presenting with Full-Thickness Macular Holes and Progression before Surgery: Implications for Optimum Management. *Ophthalmologica.* 2015;233(3-4):216-21
155. Gass JDM. Idiopathic Senile Macular Hole: Its Early Stages and Pathogenesis. *Arch Ophthalmol.* 1988;106(5):629-639
156. Chen JC. Sutureless pars plana vitrectomy through self-sealing sclerotomies. *Arch Ophthalmol* 1996;114:1273-5.
157. Fujii GY, De Juan E Jr, Humayun MS, et al. A new 25-gauge instrument system for transconjunctival sutureless vitrectomy surgery. *Ophthalmology* 2002;109:1807-12.
158. Eckardt C. Transconjunctival sutureless 23-gauge vitrectomy. *Retina* 2005;25:208-11.
159. Oshima Y, Wakabayashi T, Sato T, Ohji M, Tano Y. A 27-Gauge Instrument System for Transconjunctival Sutureless Microincision Vitrectomy Surgery. *Ophthalmology* 2010;117: 93-102.
160. Wickham L, Bunce C, Kwan AS, Bainbridge J, Aylward GW. A pilot randomised controlled trial comparing the post-operative pain experience following vitrectomy with a 20-gauge system and the 25-gauge transconjunctival system. *Br J Ophthalmol.* 2010 Jan;94(1):36-40.
161. Wimpissinger B, Kellner L, Brannath W, Krepler K, Stolba U, Mihalics C, Binder S. 23-gauge versus 20-gauge system for pars plana vitrectomy: a prospective randomised clinical trial. *Br J Ophthalmol* 2008;92:1483-1487
162. Scholz P, Müpothner PS, Schiller P, Felsch M, Fauser S. A Randomized Controlled Clinical Trial Comparing 20 Gauge and 23 Gauge Vitrectomy for Patients with Macular Hole or Macular Pucker *Adv Ther* (2018) 35:2152-2166
163. Nam Y, Chung H, Lee JY, Kim JG, Yoon YH. Comparison of 25- and 23-gauge Sutureless microincision vitrectomy surgery in the treatment of various vitreoretinal diseases. *Eye* (2010) 24, 869-874
164. Wimpissinger B, Kellner L, Brannath W, Krepler K, Stolba U, Mihalics C, Binder S. 23-gauge versus 20-gauge system for pars plana vitrectomy: a prospective randomised clinical trial. *Br J Ophthalmol* 2008;92:1483-1487
165. Scholz P, Müpothner PS, Schiller P, Felsch M, Fauser S. A Randomized Controlled Clinical Trial Comparing 20 Gauge and 23 Gauge Vitrectomy for Patients with Macular Hole or Macular Pucker *Adv Ther* (2018) 35:2152-2166
166. Nam Y, Chung H, Lee JY, Kim JG, Yoon YH. Comparison of 25- and 23-gauge Sutureless microincision vitrectomy surgery in the treatment of various vitreoretinal diseases. *Eye* (2010) 24, 869-874

167. Bahrani HM, Fazelat AA, Thomas M, Hirose T, Kroll AJ, Lou PL, Ryan EA. Endophthalmitis in the era of small gauge transconjunctival sutureless vitrectomy--meta analysis and review of literature. *Semin Ophthalmol*. 2010 Sep-Nov;25(5-6):275-82.
168. Oshima Y, Kadonosono K, Yamaji H, Inoue M, Yoshida M, Kimura H, Ohji M, Shiraga F, Hamasaki T, On Behalf Of The Japan Microincision Vitrectomy Surgery Study Group. Multicenter Survey with a Systematic Overview of Acute-Onset Endophthalmitis after Transconjunctival Microincision Vitrectomy Surgery *Am J Ophthalmol* 2010;150:716-725
169. Govetto A, Virgili G, Menchini F, Lanzetta P, Menchini U. A systematic review of endophthalmitis after microincisional versus 20-gauge vitrectomy. *Ophthalmology*. 2013 Nov;120(11):2286-91
170. Bhende M, Raman R, Jain M, Shah PK, Sharma T, Gopal L, Bhende PS, Srinivasan S, Jambulingam M; Sankara Nethralaya Vitreoretinal Study Group (SNVR-Study Group). Incidence, microbiology, and outcomes of endophthalmitis after 111,876 pars plana vitrectomies at a single, tertiary eye care hospital. *PLoS One*. 2018 Jan 16;13(1):
171. Chen G, Tzekov R, Li W, Jiang F, Mao S, Tong Y. Incidence Of Endophthalmitis After Vitrectomy A Systematic Review and Meta-analysis 2019 *RETINA* 39:844-852
172. Recchia FM, Scott IU, Brown GC, Brown MM, MD, Ho AC, Ip MS. Ophthalmic Technology Assessment. Small-Gauge Pars Plana Vitrectomy A Report by the American Academy of Ophthalmology. *Ophthalmology* 2010;117:1851-1857
173. Shields RA, Ludwig CA, Powers MA, Tran EMT, Smith SJ, Moshfeghi. Postoperative Adverse Events, Interventions, and the Utility of Routine Follow-Up After 23-, 25-, and 27-Gauge Pars Plana Vitrectomy. *Asia Pac J Ophthalmol (Phila)* 2019;8:36-42
174. Brown GT, Pugazhendhi S, Beardsley RM, Karth JW, Karth PA, Hunter AA. 25 vs. 27-gauge micro-incision vitrectomy surgery for visually significant macular membranes and full-thickness macular holes: a retrospective study. *Int J Retin Vitre* (2020) 6:56
175. Rizzo S, Belting C, Genovesi-Ebert F, Di Bartolo E. Incidence of retinal detachment after small-incision, sutureless pars plana vitrectomy compared With conventional 20-gauge Vitrectomy in macular hole and Epiretinal membrane surgery *RETINA* 30:1065-1071
176. Fujiwara N, Tomita G, Yagi F. Incidence and Risk Factors of Iatrogenic Retinal Breaks: 20-Gauge versus 25-Gauge Vitrectomy for Idiopathic Macular Hole Repair. *J Ophthalmol*. 2020 Feb 13;2020
177. Azuara-Blanco A, Carlisle A, Jayaram H, Gazzard G, Larkin DFP, Wickham L, Lois N, Bicket A. Surgical innovation in ophthalmology: challenges and opportunities. *Eye (Lond)*. 2023 Aug;37(11):2165-2166
178. Kelly NE, Wendel RT. Vitreous surgery for idiopathic macular holes. results of a pilot study. *Arch Ophthalmol* 1991;109:654-659
179. Eckardt C, Eckardt U, Groos S, et al. Removal of the internal limiting membrane in macular holes. Clinical and morphological findings. *Ophthalmologie* 1997;94:545-551
180. Wollensak G, Spoerl E, Grosse G, Wirbelauer C. Biomechanical significance of the human internal limiting lamina. *Retina* 2006;26:965-968
181. Kwok AK, Li WW, Pang CP, Lai TY, Yam GH, Chan NR, Lam DS. Indocyanine green staining and removal of internal limiting membrane in macular hole surgery: histology and outcome. *Am J Ophthalmol*. 2001 Aug;132(2):178-83.
182. Schumann RG, Rohleder M, Schaumberger MM, Haritoglou C, Kampik A, Gandorfer A. Idiopathic macular holes: ultrastructural aspects of surgical failure. *Retina*. 2008 Feb;28(2):340-9
183. Tadayoni R, Paques M, Massin P, et al. Dissociated optic nerve fiber layer appearance of the fundus after idiopathic epiretinal membrane removal. *Ophthalmology* 2001;108:2279-2283.
184. Ito Y, Terasaki H, Takahashi A, Yamakoshi T, Kondo M, Nakamura M. Dissociated optic nerve fiber layer appearance after internal limiting membrane peeling for idiopathic macular holes. *Ophthalmology*. 2005 Aug;112(8):1415-20.
185. Tsuiki E, Fujikawa A, Miyamura N, et al. Visual field defects after macular hole surgery with indocyanine green-assisted internal limiting membrane peeling. *Am J Ophthalmol* 2007;143:704-705

186. Baba T, Yamamoto S, Kimoto R, Oshitari T, Sato E. Reduction of thickness of ganglion cell complex after internal limiting membrane peeling during vitrectomy for idiopathic macular hole. *Eye (Lond)*. 2012 Sep;26(9):1173–80
187. Ishida M, Ichikawa Y, Higashida R, et al. Retinal displacement toward optic disc after internal limiting membrane peeling for idiopathic macular hole. *Am J Ophthalmol* 2014;157:971–977
188. Mason JO III, Feist RM, Albert MA Jr. Eccentric macular holes after vitrectomy with peeling of epimacular proliferation. *Retina* 2007;27:45–48
189. Rubinstein A, Bates R, Benjamin L, Shaikh A. Iatrogenic eccentric full thickness macular holes following vitrectomy with ILM peeling for idiopathic macular holes. *Eye* 2005;19: 1333–1335
190. Christensen UC, Krøyer K, Sander B, et al. Value of internal limiting membrane peeling in surgery for idiopathic macular hole stage 2 and 3: a randomised clinical trial. *Br J Ophthalmol* 2009;93:1005–1015.
191. Kwok AK, Lai TY, Wong VW. Idiopathic macular hole surgery in Chinese patients: a randomized study to compare indocyanine green assisted internal limiting membrane peeling with no internal limiting membrane peeling. *Hong Kong Medical Journal* 2005;11(4):259–66
192. Lois N, Burr J, Norrie J, et al. Internal limiting membrane peeling versus no peeling for idiopathic full-thickness macular hole: a pragmatic randomized controlled trial. *Invest Ophthalmol Vis Sci* 2011;52:1586–1592
193. Spiteri Cornish K, Lois N, Scott N, et al. Vitrectomy with internal limiting membrane (ILM) peeling versus vitrectomy with no peeling for idiopathic full-thickness macular hole (FTMH). *Cochrane Database Syst Rev* 2013;6:CD009306
194. Rahimy E, McCannel CA. Impact of internal limiting membrane peeling on macular hole reopening: a systematic review and meta-analysis. *Retina* 2016;36:679–687
195. Ternent L, Vale L, Boachie C, Burr JM, Lois N; Full-Thickness Macular Hole and Internal Limiting Membrane Peeling Study (FILMS) Group. Cost-effectiveness of internal limiting membrane peeling versus no peeling for patients with an idiopathic full-thickness macular hole: results from a randomised controlled trial. *Br J Ophthalmol*. 2012 Mar;96(3):438–43
196. Tadayoni R, Gaudric A, Haouchine B, et al. Relationship between macular hole size and the potential benefit of internal limiting membrane peeling. *Br J Ophthalmol* 2006;90:1239–1241.
197. Steel DH, Parkes C, Papastavrou VT, et al. Predicting macular hole closure with ocriplasmin based on spectral domain optical coherence tomography. *Eye* 2016;30:740–745
198. Tadayoni R, Svorenova I, Erginay A, et al. Decreased retinal sensitivity after internal limiting membrane peeling for macular hole surgery. *Br J Ophthalmol* 2012;96:1513–1516
199. Ripandelli G, Scarinci F, Piaggi P, et al. Macular pucker: to peel or not to peel the internal limiting membrane? a microperimetric response. *Retina* 2015;35:498–507
200. Krishnan R, Tossounis C, Yang YF. 20-gauge and 23-gauge phacovitrectomy for idiopathic macular holes: comparison of complications and long-term outcomes. *Eye*. 2013;27:72–77
201. Passemard M, Yakoubi Y, Muselier A, et al. Long-term outcome of idiopathic macular hole surgery. *Am J Ophthalmol*. 2010;149:120–126
202. Smiddy WE, Feuer W & Cordahi G. Internal limiting membrane peeling in macular hole surgery. *Ophthalmology*. 2001;108:1471–1476
203. D’Souza MJ, Chaudhary V, Devenyi R, et al. Re-operation of idiopathic full-thickness macular holes after initial surgery with internal limiting membrane peel. *Br J Ophthalmol*. 2011;95:1564–1567
204. Chatziralli IP, Theodossiadis PG, Steel DHW. Internal limiting membrane peeling in macular hole surgery; why, when, and how? *Retina*. 2018;38(5):870–882.
205. Kimura H, Kuroda S, Nagata M. Triamcinolone acetate-assisted peeling of the internal limiting membrane. *Am J Ophthalmol*. 2004;137 (1):172–173
206. Kadonosono K, Itoh N, Uchio E, et al. Staining of internal limiting membrane in macular hole surgery. *Arch Ophthalmol* 2000;118:1116–1118
207. Haritoglou C, Gandorfer A, Gass CA, Schaumberger M, Ulbig MW, Kampik A. Indocyanine green-assisted peeling of the internal limiting membrane in macular hole surgery affects visual outcome: a clinicopathologic correlation. *Am J Ophthalmol*. 2002;134(6):836–841

208. Engelbrecht NE, Freeman J, Sternberg P Jr, et al. Retinal pigment epithelial changes after macular hole surgery with indocyanine green-assisted internal limiting membrane peeling. *Am J Ophthalmol.* 2002;133(1):89–94
209. Ando F, Yasui O, Hirose H, Ohba N. Optic nerve atrophy after vitrectomy with indocyanine green-assisted internal limiting membrane peeling in diffuse diabetic macular edema. Adverse effect of ICG-assisted ILM peeling. *Graefes Arch Clin Exp Ophthalmol.* 2004;242(12):995–999
210. Oberstein SL, De Smet M. Use of heavy Trypan blue in macular hole surgery. *Eye.* 2010;24(7):1177–1181
211. Enaida H, Hisatomi T, Hata Y, et al. Brilliant blue G selectively stains the internal limiting membrane/brilliant blue G-assisted membrane peeling. *Retina.* 2006;26(6):631–636.
212. Matoba R, Morizane Y, Kimura S, Toshima S, Shiraga F. Retinal nerve fiber layer defect and paracentral scotoma after internal limiting membrane peeling with a nitinol loop. *Acta Med Okayama.* 2017;71(6):539–542
213. Ferrara M, Rivera-Real A, Hillier RJ, Habib M, Kadhim MR, Sandinha MT, Curran K, Muldrew A, Steel DHW. A randomised controlled trial evaluating internal limiting membrane peeling forceps in macular hole surgery. *Graefes Arch Clin Exp Ophthalmol.* 2023 Jun;261(6):1553–1562
214. Henrich PB, Monnier CA, Halfter W, et al. Nanoscale topographic and biomechanical studies of the human internal limiting membrane. *Invest Ophthalmol Vis Sci.* 2012;53(6):2561–2570.
215. Caporossi T, Carlà MM, Gambini G, De Vico U, Baldascino A, Rizzo S. Spotlight on the Internal Limiting Membrane Technique for Macular Holes: Current Perspectives. *Clin Ophthalmol.* 2022 Apr 6;16:1069–1084
216. Abdelkader E, Lois N. Internal limiting membrane peeling in vitreo-retinal surgery. *Surv Ophthalmol.* 2008;53(4):368–396.
217. Ho TC, Yang CM, Huang JS, Yang CH, Chen MS. Foveola nonpeeling internal limiting membrane surgery to prevent inner retinal damages in early stage 2 idiopathic macula hole. *Graefes Arch Clin Exp Ophthalmol.* 2014;252(10):1553–1560
218. Michalewska Z, Michalewski J, Adelman RA, Nawrocki J. Inverted internal limiting membrane flap technique for large macular holes. *Ophthalmology.* 2010;117:2018–2025
219. Khodani M, Bansal P, Narayanan R, Chhablani J. Inverted internal limiting membrane flap technique for very large macular hole. *Int J Ophthalmol.* 2016;9:1230–1232
220. Mahalingam P, Sambhav K. Surgical outcomes of inverted internal limiting membrane flap technique for large macular hole. *Indian J Ophthalmol.* 2013;61:601–603
221. Rossi T, Gelso A, Costagliola C, et al. Macular hole closure patterns associated with different internal limiting membrane flap techniques. *Graefes Arch Clin Exp Ophthalmol* 2017;255:1073–1078
222. Andrew N, Chan WO, Ebneter A, Gilhotra JS. Modification of the inverted internal limiting membrane flap technique for the treatment of chronic and large macular holes. *Retina* 2016;36:834–837
223. Michalewska Z, Michalewski J, Dulczewska-Cichecka K, Adelman RA, Nawrocki J. Temporal inverted internal limiting membrane flap technique versus classic inverted internal limiting membrane flap technique: a Comparative Study. *Retina.* 2015;35(9):1844–1850
224. Shukla D, Kalliath J, Neelakantan N, Naresh KB, Ramasamy K. A comparison of brilliant blue G, trypan blue, and indocyanine green dyes to assist internal limiting membrane peeling during macular hole surgery. *Retina.* 2011;31(10):2021–2025
225. Li SS, You R, Li M, Guo XX, Zhao L, Wang YL, Chen X. Internal limiting membrane peeling with different dyes in the surgery of idiopathic macular hole: a systematic review of literature and network Meta-analysis. *Int J Ophthalmol.* 2019 Dec 18;12(12):1917–1928
226. Modi A, Giridhar A, Gopalakrishnan M. Comparative analysis of outcomes with variable diameter internal limiting membrane peeling in surgery for idiopathic macular hole repair. *Retina.* 2017 Feb;37(2):265–273
227. Bae K, Kang SW, Kim JH, Kim SJ, Kim JM, Yoon JM. Extent of internal limiting membrane peeling and its impact on macular hole surgery outcomes: a Randomized Trial. *Am J Ophthalmol.* 2016;169:179–188

228. Sinawat S, Srihatrai P, Sutra P, Yospaiboon Y, Sinawat S. Comparative study of 1 DD and 2 DD radius conventional internal limiting membrane peeling in large idiopathic full-thickness macular holes: a randomized controlled trial. *Eye (Lond)*. 2021 Sep;35(9):2506-2513
229. Khodabande A, Mahmoudi A, Faghihi H, Bazvand F, Ebrahimi E, Riazi-Esfahani H. Outcomes of Idiopathic Full-Thickness Macular Hole Surgery: Comparing Two Different ILM Peeling Sizes. *J Ophthalmol*. 2020 Aug 18;2020:1619450
230. Yao Y, Qu J, Dong C, Li X, Liang J, Yin H, Huang L, Li Y, Liu P, Pan C, Ding X, Song D, Sadda SR, Zhao M. The impact of extent of internal limiting membrane peeling on anatomical outcomes of macular hole surgery: results of a 54-week randomized clinical trial. *Acta Ophthalmol*. 2019 May;97(3):303-312
231. Riding G, Teh BL, Yorston D, Steel DH. Comparison of the use of internal limiting membrane flaps versus conventional ILM peeling on post-operative anatomical and visual outcomes in large macular holes. *Eye (Lond)*. 2024;38(10):1876-1881.
232. Velez-Montoya R, Ramirez-Estudillo JA, Sjoholm-Gomez de Liano C, et al. Inverted ILM flap, free ILM flap and conventional ILM peeling for large macular holes. *Int J Retina Vitreous*. 2018;4(1):8
233. Manasa S, Kakkar P, Kumar A, Chandra P, Kumar V, Ravani R. Comparative Evaluation of Standard ILM Peel With Inverted ILM Flap Technique In Large Macular Holes: A Prospective, Randomized Study. *Ophthalmic Surg Lasers Imaging Retina*. 2018;49(4):236
234. Kannan NB, Kohli P, Parida H, Adenuga OO, Ramasamy K. Comparative study of inverted internal limiting membrane (ILM) flap and ILM peeling technique in large macular holes: a randomized-control trial. *BMC Ophthalmol*. 2018;18(1):177
235. Ghoraba H, Rittiphairoj T, Akhavanrezayat A, Karaca I, Matsumiya W, Pham B, Mishra K, Yasar C, Mobasserian A, Abdelkarem AA, Nguyen QD. Pars plana vitrectomy with internal limiting membrane flap versus pars plana vitrectomy with conventional internal limiting membrane peeling for large macular hole. *Cochrane Database Syst Rev*. 2023 Aug 7;8:CD015031.
236. Steel DHW, Dinah C, Magdi HA, White K, Rees J. The staining pattern of brilliant blue G during macular hole surgery: a clinicopathologic study. *Invest Ophthalmol Vis Sci*. 2014;55(9):5924-5931
237. Steel DH, Dinah C, Habib M, White K. ILM peeling technique influences the degree of a dissociated optic nerve fibre layer appearance after macular hole surgery. *Graefes Arch Clin Exp Ophthalmol*. 2015 May;253(5):691-8
238. Boninska K, Nawrocki J, Michalewska Z. Mechanism of "flap closure" after the inverted internal limiting membrane flap technique. *Retina*. 2018;38(11):2184-2189
239. Bottoni F, Parrulli S, Mete M, D'Agostino I, Cereda M, Cigada M, Maggio E, Maraone G, Iacovello D, Bottega E, Staurenghi G, Pertile G. Large Idiopathic Macular Hole Surgery: Remodelling of Outer Retinal Layers after Traditional Internal Limiting Membrane Peeling or Inverted Flap Technique. *Ophthalmologica*. 2020;243(5):334-341
240. Chen G, Tzekov R, Jiang F, Mao S, Tong Y, Li W. Inverted ILM flap technique versus conventional ILM peeling for idiopathic large macular holes: a meta-analysis of randomized controlled trials. *PLOS One* 2020;15(7):e0236431
241. Yu JG, Wang J, Xiang Y. Inverted internal limiting membrane flap technique versus internal limiting membrane peeling for large macular holes: a meta-analysis of randomized controlled trials. *Ophthalmic Research* 2021;64(5):713-22
242. Iovino C, Caminiti G, Miccoli M, Nasini F, Casini G, Peiretti E. Comparison of inverted flap and subretinal aspiration technique in full-thickness macular hole surgery: a randomized controlled study. *European Journal of Ophthalmology* 2018;28(3):324-8
243. Shen Y, Lin X, Zhang L, Wu M. Comparative efficacy evaluation of inverted internal limiting membrane flap technique and internal limiting membrane peeling in large macular holes: a systematic review and meta-analysis. *BMC Ophthalmology* 2020;20(1):14
244. Marques RE, Sousa DC, Leal I, Faria MY, Marques-Neves C. Complete ILM peeling versus inverted flap technique for macular hole surgery: a meta-analysis. *Ophthalmic Surgery, Lasers & Imaging Retina* 2020;51(3):187-A2.
245. Thompson JT, Smiddy WE, Glaser BM, et al. Intraocular tamponade duration and success of macular hole surgery. *Retina (Philadelphia, Pa)* 1996;16(5):373-82.

246. Berger JW, Brucker AJ. The magnitude of the bubble buoyant pressure: implications for macular hole surgery. *Retina* 1998;18(1):84-5
247. Alberti M, La Cour M. Gas-foveal contact: a new approach to evaluating positioning regimens in macular hole surgery. *Retina* 2018;38(5):913-21
248. Zhang Y, Chen X, Hong L, et al. Facedown positioning after vitrectomy will not facilitate macular hole closure based on swept-source optical coherence tomography imaging in gas-filled eyes: a prospective, randomized comparative interventional study. *Retina* 2019;39(12):2353-9
249. Briand S, Chalifoux E, Tourville E, Bourgault S, Caissie M, Tardif Y, Giasson M, Boivin J, Blanchette C, Cinq-Mars B. Prospective randomized trial: outcomes of SF₆ versus C₃F₈ in macular hole surgery. *Can J Ophthalmol*. 2015 Apr;50(2):95-100
250. Casini G, Loiudice P, De Cillà S, Radice P, Nardi M. Sulfur hexafluoride (SF₆) versus perfluoropropane (C₃F₈) tamponade and short-term face-down position for macular hole repair: a randomized prospective study. *Int J Retina Vitreous*. 2016 Apr 1;2:10
251. Rishi P, Rishi E, Bhende P, Bhende M, Kandle K, Attiku Y, Roy KK, Shelke K, Madaan S; SNVR groups. A prospective, interventional study comparing the outcomes of macular hole surgery in eyes randomized to C₃F₈, C₂F₆, or SF₆ gas tamponade. *Int Ophthalmol*. 2022 May;42(5):1515-1521
252. Dervenis N, Dervenis P, Sandinha T, Murphy DC, Steel DH. Intraocular Tamponade Choice with Vitrectomy and Internal Limiting Membrane Peeling for Idiopathic Macular Hole: A Systematic Review and Meta-analysis. *Ophthalmol Retina*. 2022 Jun;6(6):457-468
253. Veith M, Vránová J, Němčanský J, Studnička J, Penčák M, Straňák Z, Mojžíš P, Studený P, Piňero DP. Surgical Treatment of Idiopathic Macular Hole Using Different Types of Tamponades and Different Postoperative Positioning Regimens. *J Ophthalmol*. 2020 Dec 3;2020:8858317
254. Wong SC, Clare G, Bunce C, Sullivan PM, Gregor ZJ, Ezra E. Cataract progression in macular hole cases: results with vitrectomy or with observation. *J Cataract Refract Surg*. 2012 Jul;38(7):1176-80
255. Thompson JT. The role of patient age and intraocular gas use in cataract progression after vitrectomy for macular holes and epiretinal membranes. *Am J Ophthalmol*. 2004;137:250-7.
256. Ghosh S, Best K, Steel DH. Lens-iris diaphragm retropulsion syndrome during phacoemulsification in vitrectomized eyes. *J Cataract Refract Surg*. 2013 Dec;39(12):1852-8
257. Steel DHW. Phacovitrectomy: expanding indications. *J Cataract Refract Surg*. 2007;33(6):933-936
258. Hertzberg SNW, Veiby NCBB, Bragadottir R, Eriksen K, Moe MC, Petrovski BÉ, Petrovski G. Cost-effectiveness of the triple procedure - phacovitrectomy with posterior capsulotomy compared to phacovitrectomy and sequential procedures. *Acta Ophthalmol*. 2020 Sep;98(6):592-602
259. Farahvash A, Popovic MM, Eshtiaghi A, Kertes PJ, Muni RH. Combined versus Sequential Phacoemulsification and Pars Plana Vitrectomy: A Meta-Analysis. *Ophthalmol Retina*. 2021 Nov;5(11):1125-1138
260. Daud F, Daud K, Popovic MM, Yeung S, You Y, Cruz Pimentel M, Yan P. Combined versus Sequential Pars Plana Vitrectomy and Phacoemulsification for Macular Hole and Epiretinal Membrane: A Systematic Review and Meta-Analysis. *Ophthalmol Retina*. 2023 Aug;7(8):721-731
261. Ahoor MH, Sorkhabi R, Eftekhari Milani A, Asghari Kaleibar S. Comparison of one step macular hole and cataract surgery with two step surgery. *Guoji Yanke Zazhi (Int Eye Sci)* 2016;16(10):1795-1799
262. Viana KÍS, Gordilho CT, Almeida FPP, Esperandio MM, Lucena DR, Garcia DM, Scott IU, Messias AMV, Jorge R. Combined pars plana vitrectomy (PPV) and phacoemulsification (phaco) versus PPV and deferred phaco for phakic patients with full-thickness macular hole (FTMH) and no significant cataract at baseline: 1-year outcomes of a randomized trial combined PPV/phaco vs PPV/deferred phaco for MH. *Graefes Arch Clin Exp Ophthalmol*. 2021 Jan;259(1):29-36
263. Savastano A, Lenzetti C, Finocchio L, Bacherini D, Giansanti F, Tartaro R, Piccirillo V, Savastano MC, Virgili G, Rizzo S. Combining cataract surgery with 25-gauge high-speed pars plana vitrectomy: A prospective study. *Eur J Ophthalmol*. 2021 Mar;31(2):673-678
264. Muselier A, Dugas B, Burelle X, et al. Macular hole surgery and cataract extraction: combined vs consecutive surgery. *Am J Ophthalmol*. 2010;150(3):387-39
265. Bhatnagar P, Kaiser PK, Smith SD, Meisler DM, Lewis H, Sears JE. Reopening of previously closed macular holes after cataract extraction. *Am J Ophthalmol*. 2007 Aug;144(2):252-9

266. Wang Y, Liang X, Gao M, Liu J, Liu L, Liu W. Vision-related quality of life after pars plana vitrectomy with or without combined cataract surgery for idiopathic macular hole patients. *Int Ophthalmol*. 2019 Dec;39(12):2775-2783
267. Hamoudi H, La Cour M. Refractive changes after vitrectomy and phacovitrectomy for macular hole and epiretinal membrane. *J Cataract Refract Surg*. 2013 Jun;39(6):942-7
268. Lee JY, Kim K-H, Shin KH, Han DH, Lee DY, Nam DH. Comparison of intraoperative complications of phacoemulsification between sequential and combined procedures of pars plana vitrectomy and cataract surgery. *Retina*. 2012;32(10):2026-2033
269. Patel D, Rahman R, Kumarasamy M. Accuracy of intraocular lens power estimation in eyes having phacovitrectomy for macular holes. *J Cataract Refract Surg*. 2007 Oct;33(10):1760-2
270. Manvikar SR, Allen D, Steel DH. Optical biometry in combined phacovitrectomy. *J Cataract Refract Surg*. 2009 Jan;35(1):64-9
271. Global Trends in Retina - The American Society of Retina Specialists. <https://www.asrs.org/sections/international/globaltrends-in-retina>. Accessed May 23, 2023
272. Foster WJ, Chou T. Physical mechanisms of gas and perfluoron retinopexy and sub-retinal fluid displacement. *Phys Med Biol*. 2004 Jul 7;49(13):2989-97
273. Green WR. The macular hole: histopathologic studies. *Arch Ophthalmol*. 2006 Mar;124(3):317-21
274. Cullen R. Macular hole surgery: helpful tips for preoperative planning and postoperative face-down positioning. *J Ophthalmic Nurs Technol*. 1998;17:179e181
275. Tadayoni R, Vicaut E, Devin F, et al. A randomized controlled trial of alleviated positioning after small macular hole surgery. *Ophthalmology*. 2011;118:150e155
276. Madgula IM, Costen M. Functional outcome and patient preferences following combined phacovitrectomy for macular hole without prone posturing. *Eye (Lond)*. 2008;22: 1050e1053
277. Alberti M, la Cour M. Nonsupine positioning in macular hole surgery: a noninferiority randomized clinical trial. *Retina*. 2016;36:2072e2079
278. Lange CAK, Membrey L, Ahmad N, et al. Pilot randomized controlled trial of face-down positioning following macular hole surgery. *Eye (Lond)*. 2012;26:272e277
279. Yorston D, Siddiqui MAR, Awan MA, et al. Pilot randomized controlled trial of face-down posturing following phacovitrectomy for macular hole. *Eye (Lond)*. 2012;26:267e271
280. Chaudhary V, Sarohia GS, Phillips MR, et al. Role of Positioning after Full-Thickness Macular Hole Surgery: A Systematic Review and Meta-Analysis. *Ophthalmol Retina*. 2023 Jan;7(1):33-43. Epub 2022 Jul 1
281. Xia S, Zhao XY, Wang EQ, Chen YX. Comparison of face-down posturing with nonsupine posturing after macular hole surgery: a meta-analysis. *BMC Ophthalmol*. 2019 Jan 28;19(1):34
282. Pasu S, Bell L, Zenasni Z, et al. Facedown positioning following surgery for large full-thickness macular hole: a multicenter randomized clinical trial. *JAMA Ophthalmol*. 2020;138:725e730
283. Tsai HR, Chen TL, Chang CY, Huang HK, Lee YC. Face-Down Posture versus Non-Face-Down Posture following Large Idiopathic Macular Hole Surgery: A Systemic Review and Meta-Analysis. *J Clin Med*. 2021 Oct 24;10(21):4895
284. Hu Z, Xie P, Ding Y, Zheng X, Yuan D, Liu Q. Face-down or no face-down posturing following macular hole surgery: a meta-analysis. *Acta Ophthalmol*. 2016 Jun;94(4):326-33. Epub 2015 Sep 19.
285. Chaudhary V, Sarohia GS, Phillips MR et al. Role of Positioning after Full-Thickness Macular Hole Surgery: A Systematic Review and Meta-Analysis. *Ophthalmol Retina*. 2023 Jan;7(1):33-43
286. Xia S, Zhao XY, Wang EQ, Chen YX. Comparison of face-down posturing with nonsupine posturing after macular hole surgery: a meta-analysis. *BMC Ophthalmol*. 2019 Jan 28;19(1):34
287. Guillaubey A, Malvitte L, Lafontaine PO, et al. Comparison of facedown and seated position after idiopathic macular hole surgery: a randomized clinical trial. *Am J Ophthalmol*. 2008;146:128e134
288. Chaudhary V, Sarohia GS, Phillips MR et al. Role of Positioning after Full-Thickness Macular Hole Surgery: A Systematic Review and Meta-Analysis. *Ophthalmol Retina*. 2023 Jan;7(1):33-43. Epub 2022 Jul 1. (SIGN Grade 1++)

289. Kang, S. W., & Ahn, K. Types of macular hole closure and their clinical implications. *Br J Ophthalmol*, 2003;87, 1015–1019
290. Rossi, T., Bacherini, D., Caporossi, T., Telani, S., Iannetta, D., Rizzo, S., Moysidis, S. N., Koulisis, N., Mahmoud, T. H., & Ripandelli, G. (). Macular hole closure patterns: an updated classification. *Graefe's Archive for Clinical and Experimental Ophthalmology = Albrecht von Graefes Archiv Fur Klinische Und Experimentelle Ophthalmologie* 2020, 258(12), 2629–2638
291. Essex, R. W., Hunyor, A. P., Moreno-Betancur, M., Yek, J. T. O., Kingston, Z. S., Campbell, W. G., Connell, P. P., McAllister, I. L., Australian and New Zealand Society of Retinal Specialists Macular Hole Study Group, P., Ambler, J., Bourke, R., Branley, M., Buttery, R., Campbell, W., Chang, A., Chauhan, D., Chen, F., Chen, S., Clark, B., ... Yellachich, D. . The Visual Outcomes of Macular Hole Surgery: A Registry-Based Study by the Australian and New Zealand Society of Retinal Specialists. *Ophthalmology. Retina*, 2018, 2(11), 1143–1151
292. GASS, J. D. M. (1995). Reappraisal of Biomicroscopic Classification of Stages of Development of a Macular Hole. *American Journal of Ophthalmology*, 119(6), 752–759. [https://doi.org/10.1016/S0002-9394\(14\)72781-3](https://doi.org/10.1016/S0002-9394(14)72781-3)
293. Ch'ng, S. W., Patton, N., Ahmed, M., Ivanova, T., Baumann, C., Charles, S., & Jalil, A. The Manchester Large Macular Hole Study: Is it Time to Reclassify Large Macular Holes? *American Journal of Ophthalmology*, 2018, 195, 36–42
294. Chen, Y., Nasrulloh, A. V, Wilson, I., Geenen, C., Habib, M., Obara, B., & Steel, D. H. W. Macular hole morphology and measurement using an automated three-dimensional image segmentation algorithm. *BMJ Open Ophthalmology*, 2020, 5(1), e000404
295. Berton, M., Robins, J., Frigo, A. C., & Wong, R. Rate of progression of idiopathic full-thickness macular holes before surgery. *Eye (London, England)*, 2020, 34(8), 1386–1391
296. Madi, H. A., Dinah, C., Rees, J., & Steel, D. H. W.. The Case Mix of Patients Presenting with Full-Thickness Macular Holes and Progression before Surgery: Implications for Optimum Management. *Ophthalmologica. Journal International d'ophtalmologie. International Journal of Ophthalmology*. 2015 *Zeitschrift Fur Augenheilkunde*, 233(3–4), 216–221
297. Roth, M., Schön, N., Jürgens, L., Engineer, D., Kirchhoff, K., Guthoff, R., & Schmidt, J. (2021). Frequently assessed and used prognostic factors for outcome after macular hole surgery: which is better? *BMC Ophthalmology*, 21(1), 398. <https://doi.org/10.1186/s12886-021-02164-2>
298. Chandra, A., Lai, M., Mitry, D., Banerjee, P. J., Flayeh, H., Negretti, G., Kumar, N., & Wickham, L. (2017). Ethnic variation in primary idiopathic macular hole surgery. *Eye (London, England)*, 31(5), 708–712. <https://doi.org/10.1038/eye.2016.296>
299. Gupta, B., Laidlaw, D. A. H., Williamson, T. H., Shah, S. P., Wong, R., & Wren, S. (2009a). Predicting visual success in macular hole surgery. *The British Journal of Ophthalmology*, 93(11), 1488–1491. <https://doi.org/10.1136/bjo.2008.153189>
300. Lachance, A., Hébert, M., You, E., Rozon, J.-P., Bourgault, S., Caissie, M., Tourville, É., & Dirani, A. (2022). Prognostic Factors for Visual Outcomes in Closed Idiopathic Macular Holes after Vitrectomy: Outcomes at 4 Years in a Monocentric Study. *Journal of Ophthalmology*, 2022, 1553719. <https://doi.org/10.1155/2022/1553719>
301. Amram, A. L., Mandviwala, M. M., Ou, W. C., Wykoff, C. C., & Shah, A. R. (2018). Predictors of Visual Acuity Outcomes Following Vitrectomy for Idiopathic Macular Hole. *Ophthalmic Surgery, Lasers & Imaging Retina*, 49(8), 566–570. <https://doi.org/10.3928/23258160-20180803-03>
302. Tranos, P. G., Ghazi-Nouri, S. M. S., Rubin, G. S., Adams, Z. C., & Charteris, D. G. (2004). Visual function and subjective perception of visual ability after macular hole surgery. *American Journal of Ophthalmology*, 138(6), 995–1002. <https://doi.org/10.1016/j.ajo.2004.07.049>
303. Duan, H.-T., Chen, S., Wang, Y.-X., Kong, J.-H., & Dong, M. (2015). Visual function and vision-related quality of life after vitrectomy for idiopathic macular hole: a 12mo follow-up study. *International Journal of Ophthalmology*, 8(4), 764–769. <https://doi.org/10.3980/j.issn.2222-3959.2015.04.22>

304. Fukuda, S., Okamoto, F., Yuasa, M., Kunikata, T., Okamoto, Y., Hiraoka, T., & Oshika, T. (2009). Vision-related quality of life and visual function in patients undergoing vitrectomy, gas tamponade and cataract surgery for macular hole. *The British Journal of Ophthalmology*, 93(12), 1595–1599. <https://doi.org/10.1136/bjo.2008.155440>
305. Hirneiss, C., Neubauer, A. S., Gass, C. A., Reiniger, I. W., Priglinger, S. G., Kampik, A., & Haritoglou, C. (2007). Visual quality of life after macular hole surgery: outcome and predictive factors. *The British Journal of Ophthalmology*, 91(4), 481–484. <https://doi.org/10.1136/bjo.2006.102376>
306. Okamoto, F., Okamoto, Y., Fukuda, S., Hiraoka, T., & Oshika, T. (2010). Vision-related quality of life and visual function after vitrectomy for various vitreoretinal disorders. *Investigative Ophthalmology & Visual Science*, 51(2), 744–751. <https://doi.org/10.1167/iovs.09-3992>
307. Lois, N., Burr, J., Norrie, J., Vale, L., Cook, J., McDonald, A., Boachie, C., Ternent, L., & McPherson, G. (2011). Internal Limiting Membrane Peeling versus No Peeling for Idiopathic Full-Thickness Macular Hole: A Pragmatic Randomized Controlled Trial. *Investigative Ophthalmology & Visual Science*, 52(3), 1586. <https://doi.org/10.1167/iovs.10-6287>
308. Arimura, E., Matsumoto, C., Okuyama, S., Takada, S., Hashimoto, S., & Shimomura, Y. (2007). Quantification of metamorphopsia in a macular hole patient using M-CHARTS. *Acta Ophthalmologica Scandinavica*, 85(1), 55–59. <https://doi.org/10.1111/j.1600-0420.2006.00729.x>
309. McGowan, G., Yorston, D., Strang, N. C. N. C., & Manahilov, V. (2015). D-CHART: A Novel Method of Measuring Metamorphopsia in Epiretinal Membrane and Macular Hole. *Retina (Philadelphia, Pa.)* 2016;36(4):703-8310
310. Isernhagen RD, Michels RG, Glaser BM, de Bustros S, Enger C. Hospitalization Requirements After Vitreoretinal Surgery. *Arch Ophthalmol*. 1988;106(6):767–770.
311. Newsom R, Luff A, Wainwright C, Canning C. UK survey of attitudes to local anaesthesia for vitreoretinal surgery. *Eye (Lond)* 2001; 15(Pt 6): 708–711.
312. Yannuzzi NA, Sridhar J, Flynn HW Jr, Gayer S, Berrocal AM, Patel NA, Townsend J, Smiddy WE, Albin T. Current Trends in Vitreoretinal Anesthesia. *Ophthalmol Retina*. 2019 Sep;3(9):804–805
313. Alexander P, Michaels L, Newsom R. Is day-1 postoperative review necessary after pars plana vitrectomy? *Eye (Lond)*. 2015 Nov;29(11):1489–94.
314. Wong R, Gupta B, Williamson TH, Laidlaw DA. Day 1 postoperative intraocular pressure spike in vitreoretinal surgery (VDOP1). *Acta Ophthalmol* 2011; 89(4): 365–368.
315. Ringeisen AL, Parke DW 3rd. Reconsidering the Postoperative Day 0 Visit for Retina Surgery. *Ophthalmic Surg Lasers Imaging Retina*. 2018 Sep 1;49(9):e52–e56.
316. Bheemidi AR, Roan VD, Muste JC, Singh RP. (2021) Examining the Necessity of Postoperative Day-1 Review After Pars Plana Vitrectomy: A Meta-Analysis. *Ophthalmic Surg Lasers Imaging Retina*. 2021;52(9):513–518.
317. Ahn SJ, Woo SJ, Ahn J, Park KH. Comparison of postoperative intraocular pressure changes between 23-gauge transconjunctival sutureless vitrectomy and conventional 20-gauge vitrectomy. *Eye (Lond)*. 2012;26(6):796–802.
318. Kaźmierczak K, Stafiej J, Stachura J, Żuchowski P, Malukiewicz G. Long-Term Anatomic and Functional Outcomes after Macular Hole Surgery. *J Ophthalmol*. 2018 Nov 26;2018:3082194.
319. Leonard RE 2nd, Smiddy WE, Flynn HW Jr, Feuer W. Long-term visual outcomes in patients with successful macular hole surgery. *Ophthalmology*. 1997 Oct;104(10):1648–52.
320. Brennan N, Reekie I, Ezra E, Barton K, Viswanathan A, Muqit MM. The role of day one postoperative review of intraocular pressure in modern vitrectomy surgery. *Br J Ophthalmol*. 2017 Sep;101(9):1281–1284. Grade 2–
321. Benz MS, Escalona-Benz EM, Murray TG et al. Immediate postoperative use of a topical agent to prevent intraocular pressure elevation after pars plana vitrectomy with gas tamponade. *Arch Ophthalmol* 2004; 122(5): 705–709. Grade 1–
322. Sciscio A, Casswell AG. Effectiveness of apraclonidine 1% in preventing intraocular pressure rise following macular hole surgery. *Br J Ophthalmol* 2001; 85(2): 164–168. Grade 1–

323. Tan HT, Duker, J. S., Kaiser, P. K., Binder, S., de Smet, M. D., Gaudric, A., Reichel, E., Sadda, S. R., Sebag, J., Spaide, R. F., & Stalmans, P.. The International Vitreomacular Traction Study Group classification of vitreomacular adhesion, traction, and macular hole. *Ophthalmology*, 2013, 120(12), 2611–2619 Lesnik-Oberstein SY, Mura M and de Smet M Enhanced internal search for iatrogenic retinal breaks in 20-gauge macular surgery. *Br J Ophthalmol* 2010; 94: 1490–92 (SIGN 3)
324. Mura M, Barca F Dell’Omo R, Nasini F and Peiretti E Iatrogenic breaks in ultrahigh-speed 25 gauge vitrectomy: a prospective study of elective cases. *Br J Ophthalmol* 2016; 100:1383-1387 (SIGN 2-)
325. Chung SE, Kim KH & Kang SW. Retinal breaks associated with the induction of posterior vitreous detachment *Am J Ophthalmol* 6, 2009;147: 1012-1016C (SIGN 3)
326. Fajgenbaum M, Neffendorf JE, Wong RS, Laidlaw DAH and Williamson TH Intraoperative and postoperative complications in phacovitrectomy for epiretinal membrane and macular hole. *Retina* 2018; 38:1865-1872 (SIGN 3)
327. Pillai GS, Verkey R, Unnikrishnan UG and Radhakrishnan N Incidence and risk factors for intraocular pressure rise after transconjunctival vitrectomy. *Ind J Ophthalmol*, 2020;68:812-7 (SIGN 3)
328. Toyokawa N, Kimura H, Matsumura M and Kuroda S Incidence of late-onset ocular hypertension following uncomplicated pars plana vitrectomy in pseudophakic eyes. *Am J Ophthalmol*, 2015; 159: 727-732 (SIGN 3)
329. Jairath N, Paulus YM, Yim A, Zhou Y, Parekh BJ, Jairath R, Musch DC and Rosenthal JM intra- and post-operative risk of retinal breaks during vitrectomy for macular hole and vitreomacular traction. *PLoS ONE*, 2022; 17(8): e0272333 2022
330. Cullinane A and Cleary PE. Prevention of visual field defects after macular hole surgery. *Br J Ophthalmol* 2000; 84: 372-377
331. Gass CA, Haritoglou C, Messmer EM, et al. Peripheral visual field defects after macular hole surgery: a complication with decreasing incidence *Br J Ophthalmol* 5, 2001;85: 549-551
332. Rahman R, Oxley L and Stephenson J Persistent outer retinal fluid following non-posturing surgery for idiopathic macular hole. *Br J Ophthalmol*, 2013; 97: 1451-1454
333. Kang SEW, Lim JW, Chung SEA and Chan-Hui Y. Outer foveolar defect after surgery for idiopathic macular hole. *Am J Ophthalmol*, 2010;150:551-557
334. Kawano H, Uemura A and Sakamoto T. Incidence of outer foveal defect after macular hole surgery. *Am J Ophthalmol* 2011; 151: 318-322
335. Sandali O, Sanhrawi M El, Basli E, Lecuen N, Bonnel S, Borderie V, Laroche and Monin C. Paracentral retinal holes occurring after macular surgery: incidence, clinical features and evolution. *Graefe’s Arch Clin Exp Ophthalmol*, 2012;250(8):1137-42.336
336. Brouzas D, Dettoraki M, Lavaris A et al. Postoperative eccentric macular holes after vitrectomy and internal limiting membrane peeling.. *Int Ophthalmol* 2017; 37:643-648
337. Anikina E, Wagner SK, Liyanage S, Sullivan P, Pavesio C, Okhravi N. The Risk of Sympathetic Ophthalmia after Vitreoretinal Surgery. *Ophthalmol Retina*. 2022 May;6(5):347-360. (SIGN 2-)
338. Ripa M, Panos GD, Rejdak R, Empeslidis T, Toro MD, Costagliola C, Ferrara A, Gotzaridis S, Frisina R, Motta L. Sympathetic Ophthalmia after Vitreoretinal Surgery without Antecedent History of Trauma: A Systematic Review and Meta-Analysis. *J Clin Med*. 2023 Mar 16;12(6):2316. (Sign 1+)
339. Tyagi M., Agarwal K., Reddy Pappuru R.R., Dedhia C., Agarwal H., Nayak S., Panchal B., Kaza H., Basu S., Pathengay A., et al. Sympathetic ophthalmia after vitreoretinal surgeries: Incidence, clinical presentations and outcomes of a rare disease. *Semin. Ophthalmol*. 2019;34:157–162. (SIGN 2-)
340. Eckardt C, Eckert T, Eckardt U, Porkert U, Gesser C. Macular hole surgery with air tamponade and optical coherence tomography-based duration of face-down positioning. *Retina*. 2008 Oct;28(8):1087-96
341. Distelmaier P, Meyer LM, Fischer MT, Philipp S, Paquet P, Mammen A, Haller K, Schönfeld CL. Delayed macular hole closure. *Case Rep Ophthalmol*. 2014 Apr 10;5(1):121-4.

342. Thompson JT, Sjaarda RN, Lansing MB. The results of vitreous surgery for chronic macular holes. *Retina*. 1997;17(6):493-501
343. Baumann C, El-Faouri M, Ivanova T, Patton N, Ch'ng SW, Dhawahir-Scala F, Jalil A. MANCHESTER REVISIONAL MACULAR HOLE STUDY: Predictive Value of Optical Coherence Tomography Parameters on Outcomes of Repeat Vitrectomy, Extension of Internal Limiting Membrane Peel, and Gas Tamponade for Persistent Macular Holes. *Retina*. 2021 May 1;41(5):908-914. SIGN Grade 2-
344. Chen, Y. Y. and C. M. Yang (2022). Intravitreal gas injection for early persistent macular hole after primary pars plana vitrectomy. *BMC Ophthalmology* 22(1): 369. SIGN Grade 2-
345. Hillenkamp J, Kraus J, Framme C, Jackson TL, Roider J, Gabel VP, Sachs HG. Retreatment of full-thickness macular hole: predictive value of optical coherence tomography. *Br J Ophthalmol*. 2007 Nov;91(11):1445-9. SIGN Grade 2-
346. Lorenzi U, Mehech J, Caporossi T, Romano MR, De Fazio R, Parrat E, Matonti F, Mora P; ReMaHo Study Group. A retrospective, multicenter study on the management of macular holes without residual internal limiting membrane: the refractory macular hole (ReMaHo) study. *Graefes Arch Clin Exp Ophthalmol*. 2022 Dec;260(12):3837-3845. SIGN Grade 2-
347. Maguire MJ, Steel DH, Yorston D, Hind J, El-Faouri M, Jalil A, Tyagi P, Wickham L, Laidlaw AH. OUTCOME OF REVISION PROCEDURES FOR FAILED PRIMARY MACULAR HOLE SURGERY. *Retina*. 2021 Jul 1;41(7):1389-1395. SIGN Grade 2-
348. Szurman P, Wakili P, Stanzel BV, Siegel R, Boden KT, Rickmann A. Persistent macular holes - what is the best strategy for revision? *Graefes Arch Clin Exp Ophthalmol*. 2021 Jul;259(7):1781-1790. SIGN Grade 2-
349. Frisina R, Gius I, Tozzi L, Midena E. Refractory full thickness macular hole: current surgical management. *Eye (Lond)*. 2022 Jul;36(7):1344-1354. SIGN Grade 2-
350. Reid GA, McDonagh N, Wright DM, Yek JTO, Essex RW, Lois N. First Failed Macular Hole Surgery Or Reopening Of A Previously Closed Hole: Do We Gain by Reoperating? A Systematic Review and Meta-analysis. *Retina*. 2020 Jan;40(1):1-15. SIGN Grade 2++
351. Yek JTO, Hunyor AP, Campbell WG, McAllister IL, Essex RW; Australian and New Zealand Society of Retinal Specialists Macular Hole Study Group. Outcomes of Eyes with Failed Primary Surgery for Idiopathic Macular Hole. *Ophthalmol Retina*. 2018 Aug;2(8):757-764. SIGN Grade 2-
352. Patel R, Gopalakrishnan M, Giridhar A. TIMING AND OUTCOME OF SURGERY FOR PERSISTENT MACULAR HOLE. *Retina*. 2019 Feb;39(2):314-318. SIGN Grade 2-
353. Maguire MJ, Steel DH, Yorston D, Hind J, El-Faouri M, Jalil A, Tyagi P, Wickham L, Laidlaw AH. OUTCOME OF REVISION PROCEDURES FOR FAILED PRIMARY MACULAR HOLE SURGERY. *Retina*. 2021 Jul 1;41(7):1389-1395. SIGN Grade 2-
354. Caporossi T, Tartaro R, Finocchio L, Pacini B, De Angelis L, Bacherini D, Rizzo S. HUMAN AMNIOTIC MEMBRANE TO TREAT MACULAR HOLES THAT FAILED TO CLOSE, SULFUR HEXAFLUORIDE ENDOTAMPONADE VERSUS AIR ENDOTAMPONADE: A Prospective Comparative Study. *Retina*. 2021 Apr 1;41(4):735-743. SIGN Grade 1-
355. Cillino S, Cillino G, Ferraro LL, Casuccio A. TREATMENT OF PERSISTENTLY OPEN MACULAR HOLES WITH HEAVY SILICONE OIL (DENSIRON 68) VERSUS C2F6. A PROSPECTIVE RANDOMIZED STUDY. *Retina*. 2016 Apr;36(4):688-94. SIGN Grade 1-
356. Abbey AM, Van Laere L, Shah AR, Hassan TS. Recurrent Macular Holes In The Era Of Small-Gauge Vitrectomy: A Review of Incidence, Risk Factors, and Outcomes. *Retina* 2017;37:921-924.
357. Yoshida M, Kishi S. Pathogenesis of Macular Hole Recurrence and its Prevention by Internal Limiting Membrane Peeling. *Retina* 27:169-173, 2007
358. Valldeperas X, Wong D. Is it worth reoperating on macular holes? *Ophthalmology*. 2008 Jan;115(1):158-63.
359. Kamyar Vaziri, Schwartz SG, Kishor KS, Fortun JA, Moshfeghi AA, Smiddy WE, Flynn JW Rates of Reoperation and Retinal Detachment after Macular Hole Surgery. *Ophthalmology* 2016;123:26-31. SIGN Grade 2-
360. Kumagai K, Furukawa M, Ogino N, Larson E. Incidence and Factors Related to Macular Hole Reopening. *Am J Ophthalmol* 2010;149:127-132. SIGN Grade 2-

361. Szigiato A, Gilani F, Walsh MK, Mandelcorn ED, Muni RH Induction Of Macular Detachment For The Treatment Of Persistent Or Recurrent Idiopathic Macular Holes. *Retina* 2016;36:1694–1698. SIGN Grade 3
362. Grewal DS, Charles S, Parolini B, Kadonosono K, Mahmoud TH. Autologous Retinal Transplant for Refractory Macular Holes: Multicenter International Collaborative Study Group *Ophthalmology* 2019;126:1399-1408 SIGN Grade 3
363. Smiddy WE. Macular hole formation without vitreofoveal traction. *Arch Ophthalmol* 2008;126:737–738.
364. Bonnell AC, Prenner S, Weinstein MS, Fine HF: Macular Hole Closure with Topical Steroids. *Retinal Cases & Brief Reports* 16:351–354, 2022
365. Richards PJ, Kulkarni AD, Nork TM, Leys M, Hinkle D, Conlin KA, Chang S, Chang JS: Nonsurgical Resolution of Full Thickness Macular Holes without Vitreomacular Traction. *Retin Cases Brief Rep.* 2023 Sep 1;17(5):584-587.
366. Kokame GT, Johnson MW, Lim J, Flynn HW, de Carlo T, Yannuzzi N, Ryan EH, Omizo JN, Sridhar J, Staropoli P, Goldhagen B, Lian R: Closure of Full-Thickness Macular Holes Associated with Macular Edema with Medical Therapy. *Ophthalmologica* 2022;245:179-186.
367. Kurz PA, Kurz DE. Macular hole closure and visual improvement with topical nonsteroidal treatment. *Arch Ophthalmol.* 2009 Dec;127(12):1687-8. SIGN Grade 3
368. Small KW, Avetisjan J, Shaya FS. Closure of Macular Holes With Topical Therapy. *J Vitreoretin Dis.* 2022 Dec 13;7(2):109-115. SIGN Grade 2-
369. Sokol JT, Schechet SA, Komati R, Elliott D, Vavvas DG, Kaplan RI, Ittiara ST, Farooq AV, Sheth VS, MacCumber MW, Ke R, Gentile RC, Skondra D. Macular Hole Closure with Medical Treatment. *Ophthalmol Retina.* 2021 Jul;5(7):711-713. SIGN Grade 3
370. Gonzalez-Saldivar G, Juncal V, Chow D. Topical steroids: A non-surgical approach for recurrent macular holes. *Am J Ophthalmol Case Rep.* 2018 Dec 18;13:93-95. SIGN Grade 3
371. Khurana RN, Wieland MR. Topical Steroids for Recurrent Macular Hole after Pars Plana Vitrectomy. *Ophthalmol Retina.* 2018 Jun;2(6):636-637. SIGN Grade 3

18 Stephenson Way
London, NW1 2HD

T. 020 7935 0702
contact@rcophth.ac.uk



rcophth.ac.uk
[@RCOphth](https://twitter.com/RCOphth)